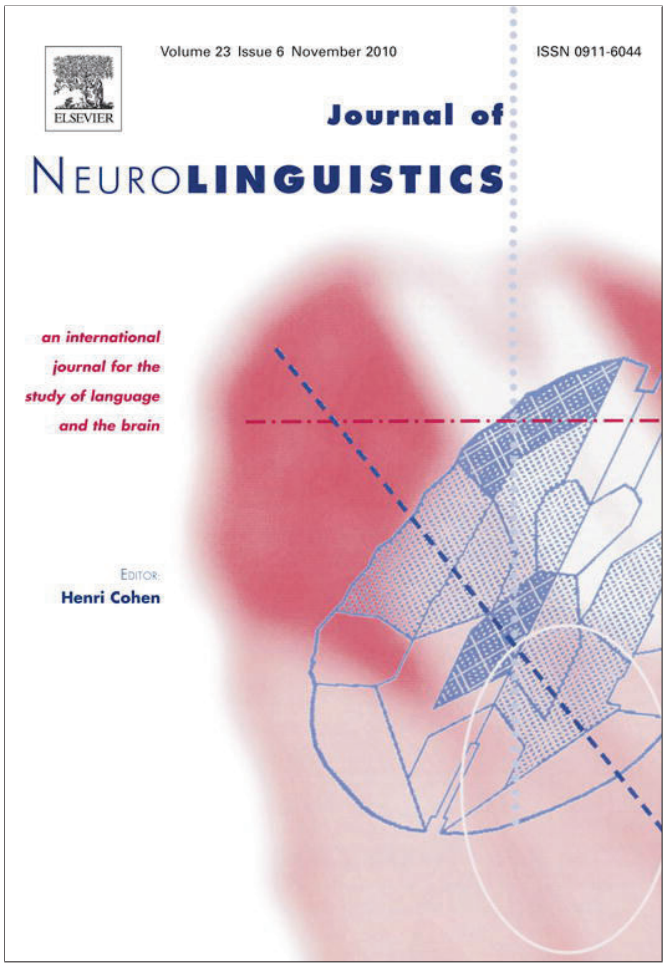

Journal of Neurolinguistics 23 (2010) 531–539

Contents lists available at ScienceDirect

Journal of Neurolinguistics

journal homepage: www.elsevier.com/locate/jneuroling

Subcortical organization of languages in bilingual brain

Mahmoud Reza Azarpazhooh [a,1], Nader Jahangiri [b,2], Maryam Ghaleh [b,*]

[a] Department of Neurology, Mashhad University of Medical Sciences, Ghaem University Hospital, Mashhad, Iran
[b] Department of Linguistics, Ferdowsi University of Mashhad, Mashhad, Iran

ARTICLE INFO

Article history:
Received 15 August 2009
Received in revised form 22 March 2010
Accepted 22 March 2010

Keywords:
Subcortical bilingual aphasia
Subcortical organization of language
Striatocapsular area
Language disorder
Pattern of recovery

ABSTRACT

One of the most important and least studied issues in neurolinguistics is the subcortical organization of languages in the bilingual brain. In this paper, the linguistic disorders and patterns of recovery in three aphasic patients with subcortical lesions in striatocapsular area have been studied. It was concluded that in bilinguals, languages might be lateralized in subcortical areas of the left hemisphere and that these subcortical structures might be more involved in speech production than comprehension. It was also suggested that the first language might have more subcortical representation than the second language and the subcortical organization of languages in bilingual brain can change according to the age of acquisition of second language.

1. Introduction

The organization of language in the brain has always been an interesting issue for linguists and neurologists. Although approximately 80% of the world is bilingual, and 75% is illiterate the current state of knowledge on the cerebral organization of language is based almost entirely on research conducted with literate monolinguals (Porch & de Berkeley-Wykes, 1985).

According to current linguistic, psychological, and neurolinguistic approaches, the term "bilingual" refers to all those people who use two or more languages or dialects in their everyday lives (Fabbro, 2001a). Bilingualism does not imply a specific degree of proficiency in one or the other language (Meinzer, Obleser, Flaisch, Eulitz, & Rockstroh, 2007).

* Corresponding author. 93 Taavon 7 St., Samaneh 1 St., FerdowsiBlvd., Mashhad 9197999449, Iran. Tel.: +98 915 512 0341.
E-mail addresses: r_azarpazhooh@yahoo.com (M.R. Azarpazhooh), jahangiri398@yahoo.com (N. Jahangiri), maryam2133@yahoo.com (M. Ghaleh).
[1] Tel.: +98 511 801 2514 (Office).
[2] Tel.: +98 915 115 8578.

0911-6044/$ – see front matter © 2010 Elsevier Ltd. All rights reserved.
doi:10.1016/j.jneuroling.2010.03.007

From the neurolinguist's perspective, the monolingual may be considered an unmarked case of brain organization for language and the bilingual as interesting modification that pushes us further to think about what we know about the ways the brain can be organized for language (Obler & Gjerlow, 2000). One might expect that bilingual aphasics lose the two languages they spoke before insult to an extent proportional to their relative premorbid degree of mastery (parallel recovery). It is indeed often the case that they do, but not always. Sometimes polyglots become aphasic for only one or two of the languages they knew (selective aphasia). Sometimes they recover one language better than the other (differential recovery), or one after the other has been maximally recovered (successive recovery). Sometimes one of the languages is not recovered and remains forever unavailable (selective recovery) or the better recovered language deteriorates as the other improves (antagonistic recovery). Sometimes the first recovered language deteriorates several times in succession, so that each language is only alternatively available (alternate antagonistic recovery). In some cases the patient systematically mixes the two languages inextricably (mixed recovery) (Paradis, 1987). Recently the study of the linguistic behavior of bilingual aphasics has added to our knowledge about cortical organization of languages in bilingual brain. Paradis suggested that there is no evidence of a difference in the lateralization of language system between bilinguals and monolinguals. Nor is there any evidence that languages of bilinguals are each represented in different locus in the brain. He believed that cerebral representation of languages in bilinguals may be different at the microanatomical level (Paradis, 2004).

Traditionally, aphasia has been regarded only as a language disorder caused by the damage to the language areas of the dominant cerebral cortex. However, since the late 1970s, this traditional view has been challenged by the findings of an increasing number of cliniconeuroradiological correlation studies that have documented the occurrence of adult language disorders in association with apparently subcortical vascular lesions (Murdoch, 2004). As the result of these studies and the observation of cases with subcortical lesions suffering from language disorders, it was hypothesized that subcortical areas might be involved in language processing. Later studies determined some subcortical structures which had a role in language processing.

Subcortical structures which are often claimed to have linguistic roles include basal ganglia, the thalamus, the subcortical white matter pathways and cerebellum (Murdoch, 2004). Lesions in the area called striatocapsular or striatocapsular strokes have also caused language disorders in some cases. This area includes caudate nucleus, putamen, globus pallidus and anterior and posterior parts of internal capsule and subinsular area (Chung et al., 2000).

As noted earlier, the organization of language in bilingual brain is relatively different with that in a monolingual brain. However, studies on the subcortical organization of language in bilingual brain are very rare and only a few cases of bilingual subcortical aphasia have been reported (Aglioti, Beltramello, Girardi, & Fabbro, 1996).

In 1960s, Kainz suggested that often the best recovered language was a language the use of which was not automatic but rather depended on conscious efforts. He is of the opinion that aphasia mainly affects the most automatic language, namely the language which was used unconsciously (as cited in Fabbro, 2001b, p. 213). According to Fabbro, when a second language is learned formally and mainly used at school, it apparently tends to be more widely represented in the cerebral cortex than the first language. However, if it is acquired informally, as usually happens with the first language, it is more likely to involve subcortical structures (Fabbro, 2001b).

In 1996, Aglioti et al. reported the case of a bilingual aphasic patient (E.M.) with subcortical lesions mainly involving the left basal ganglia. This patient had more severe disorders in her most used mother tongue and her second language was the best recovered language. It was proposed that this type of recovery was related to the higher degree of automatization of the first language with respect to the second one (Aglioti et al., 1996).

The present study seeks to explore subcortical bilingual aphasia and subcortical organization and lateralization of first and second languages in Farsi-speaking bilinguals and to examine the validity of the hypothesis of more subcortical involvement in the bilingual's first language. The subjects of this study comprised 3 adult bilingual patients with symptoms of aphasia as a result of striatocapsular stroke. All three patients are from Sabzevar and Ghuchan, north east Iran, with a local Turkish mother tongue and Farsi as their second language. These patients' languages were assessed by means of Bilingual Aphasia Test (BAT).

2. Case report

2.1. Case 1 (S.S.A.[3])

S.S.A is an 82-year-old right-handed uneducated female who had learned Farsi when she was 8 and could use both languages fluently. She had a stroke in 2006 and was referred to us in 2008 for linguistic assessments.

2.1.1. Clinical history

S.S.A. had an infarction in 2006 which caused her right hemiplegia. The CT scan of her brain showed a lesion in the left striatocapsular area (basal ganglia) (Fig. 1). She has been suffering from intensive motor disorder in the right part of her body and subcortical aphasia. The patient did not have any speech therapy or physiotherapy.

2.1.2. Language assessment (October 2008)

S.S.A. was referred to us for linguistic assessments on 7 October 2008 when she was unable to speak any of her languages.

She was given a Farsi language modified version of Bilingual Aphasia Test on the same day and a Turkish language modified version of BAT two weeks later. S.S.A was not able to produce speech in any of her languages and, as her family claimed, has not spoken a word after the stroke. The only sound she could produce in answering the questions was a cluster of particular sounds which she used with the same order but different intonations in order to convey different senses. This sound cluster was /yebebebebe/. The patient could not pronounce this cluster in separate syllables. As an example, she was asked to produce/be/or/ye/but she could not. She was, however, able to express herself with body language which was also limited because of her motor deficits. For example, she could give positive or negative answers by head movements.

Patient's performance in pointing task was very weak. Generally, she could not get the meaning easily and everything had to be named several times for her so that she could point at it. She performed relatively well in simple and semi-complex commands. She was not able to perform any of the complex commands in either language. The commands should be read one by one so that she could respond to one, two or three commands. Her performance in all above tasks was better in Turkish.

The patient's verbal auditory discrimination was relatively weak in both languages. She was also very weak in performing syntactic comprehension task. She seemed to understand none of the sentences and pointed at a picture at random, sometimes even before the sentence was completely read. Since S.S.A. was unable to produce speech, she could not perform other tasks such as naming and repetition.

According to the test results, this patient had severe speech production disorders and impaired comprehension. Her pattern of recovery was differential 31 months post-onset and Turkish, her mother tongue, was her best recovered language.

2.2. Case 2 (M.M.)

M.M. was a 73-year-old right-handed man who learned Farsi when he was 2 or 3. He used to speak to his friend in both languages in childhood but mostly spoke Turkish at home (Fig. 1).

2.2.1. Clinical history

The patient was an illiterate farmer. He had a stroke in 2007 which caused him severe motor disorders and aphasia. CT scan of his brain revealed a lesion in left striatocapsular area (Fig. 2). He had no speech therapy or physiotherapy after the stroke.

2.2.2. Language assessment (October 2008)

M.M. referred to us 12 months post-onset, on 22 October 2008. He had disorders in both languages and his aphasia was diagnosed as subcortical. A Farsi test was given to him on the same day and

[3] Patient's name in abbreviation.

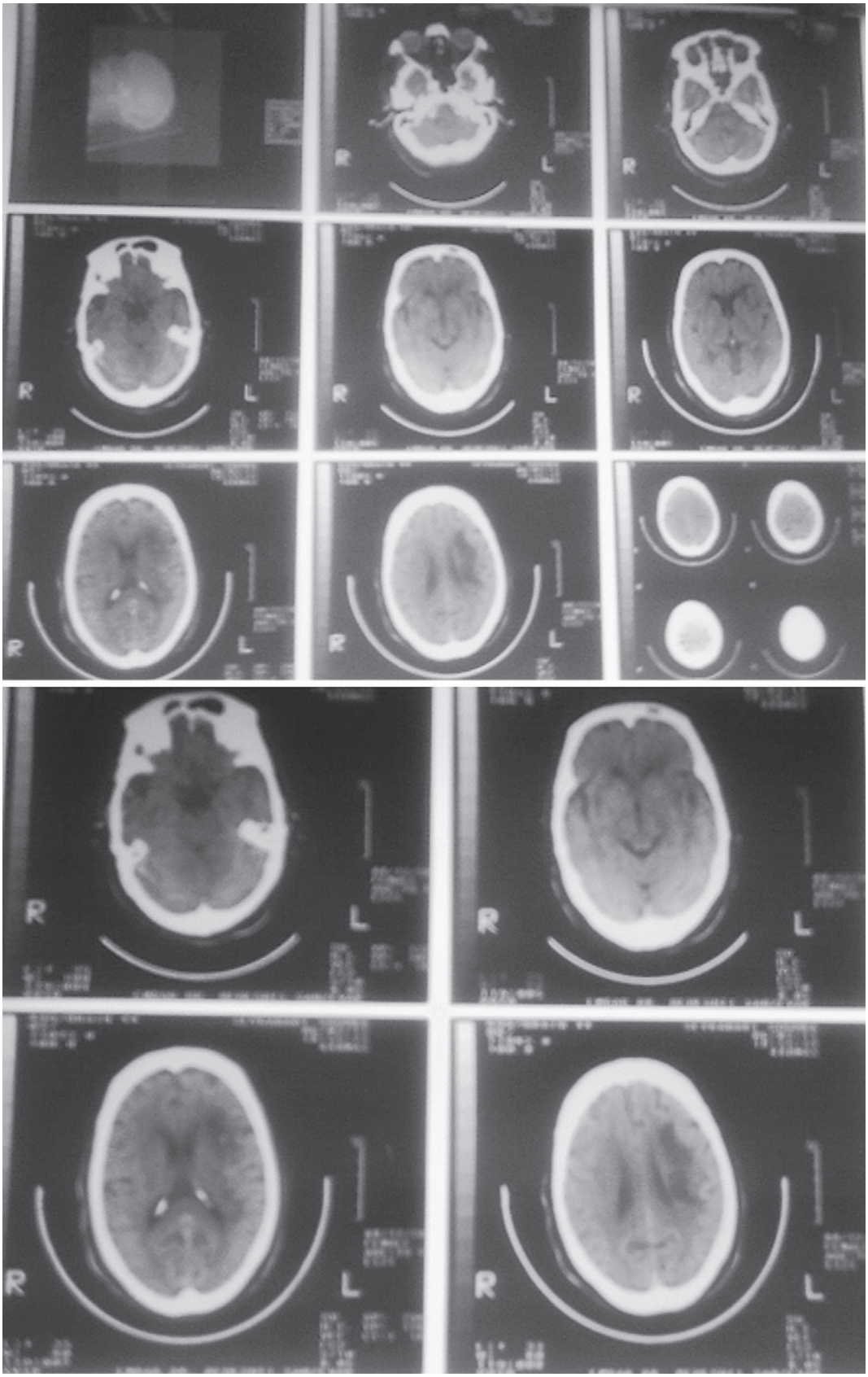

Fig. 1. CT scan of case 1 (S.S.A.). Lesion can be seen in the left basal ganglia.

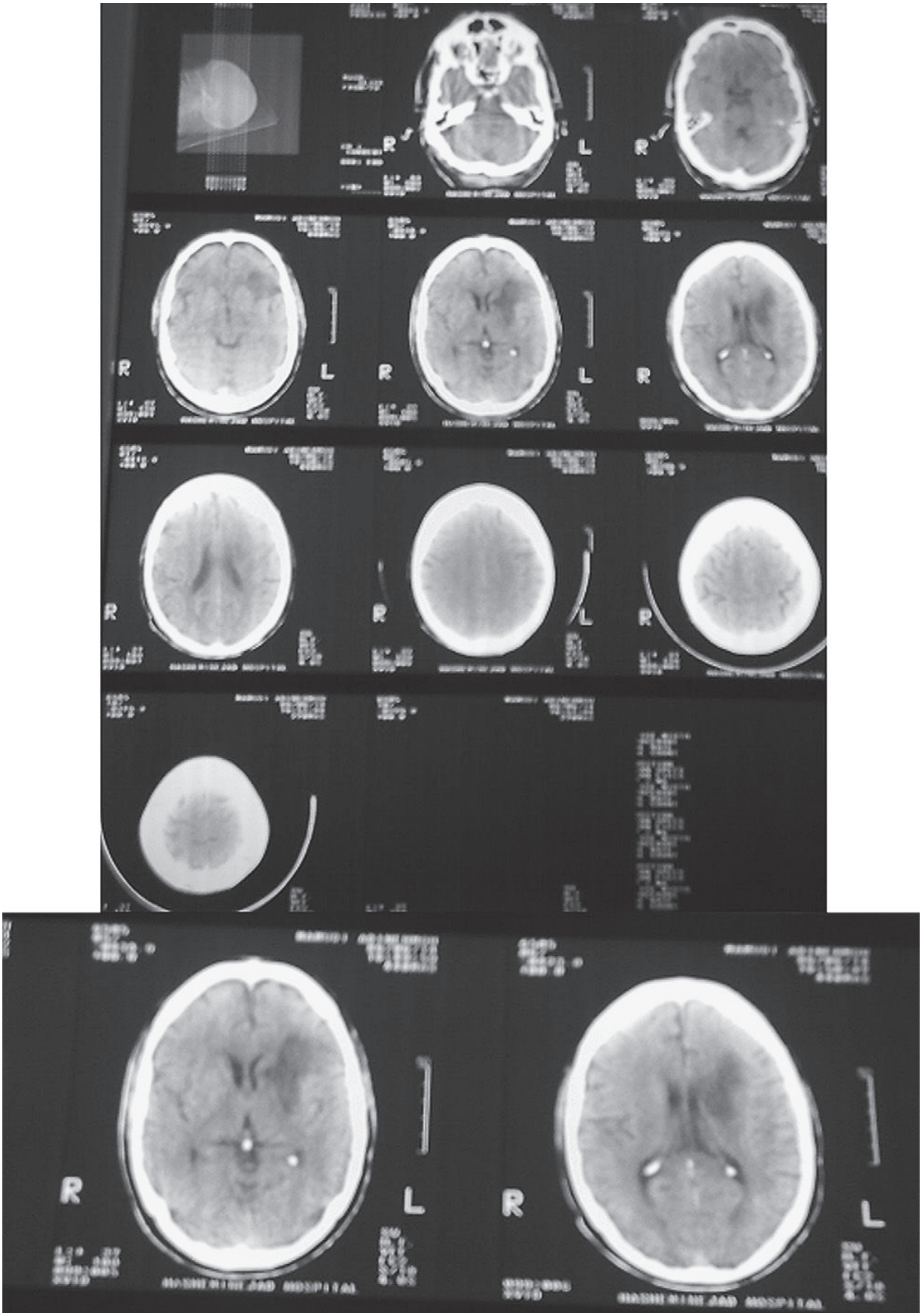

Fig. 2. CT scan of case 2 (M.M.). Lesion can be seen in the left striatocapsular area.

a Turkish one on the following day. The patient was aware of his disorders and made efforts to improve his speech. Whenever he could not express himself, he cried.

M.M. had many problems in producing spontaneous speech. His speech was slow, nonfluent, effortful and interrupted, containing a relatively large number of repetitions. The length of utterances he produced was very short and he mostly used simple and non-complex sentences without verb. His vocabulary was very limited, particularly in Farsi. He had some word-finding difficulties and as a result of paraphasias resulting in nonwords, many of the words he produced in both languages were incomprehensible. M.M.'s speech was grammatical and he had no difficulty in using grammatical words and correct word orders. Moreover, his speech was coherent and pragmatically correct.

M.M. had some difficulty in performing pointing task. He did well at simple and semi-complex commands tasks in Turkish. However, in Farsi, the commands were needed to be repeated several times and he performed them with difficulty and, sometimes, wrong. In the task of complex commands, M.M.'s performance was weak. He had difficulties in verbal auditory discrimination and syntactic comprehension tasks as well. M.M. could not answer any of the questions in synonyms task and had difficulties in answering the antonyms one.

The patient's repetition of words and sentences was good but better in Turkish. He had several phonemic paraphasic problems in repetition of Farsi words. His lexical decision was spared in Turkish but totally impaired in Farsi.

M.M. could produce series; however, in verbal fluency task, he could not say even a word. His naming was spared in both languages. Nevertheless, in sentence construction and semantic opposites tasks, the patient's performance was very weak.

According to the BAT results, M.M.'s production was more impaired than his comprehension and his naming and repetition were spared. He had subcortical aphasia and differential pattern of recovery 12 months post-onset. His best recovered language was Turkish which was his mother tongue and the dominant language of his environment after the stroke.

2.3. Case 3 (F.Gh.)

F.Gh. is a 52-year-old right-handed female who has 12 years of education and is a retired elementary-school teacher. The language of education at her school had been Farsi. It was also the language she used at work. Her husband is also a bilingual and she mostly spoke Turkish with him. Therefore, Farsi was mostly her language of education and work. F.Gh. had a stroke in 2008 and referred to us in 2009. She could speak both Farsi and Turkish fluently before stroke.

2.3.1. Clinical history

F.Gh. had a stroke on 16 January 2008 which caused her right hemiplegia. CT scan of her brain revealed a lesion in left striatocapsular area (Fig. 3). After the stroke, patient had severe motor disorders in the right part of her body and subcortical aphasia. She has had some speech therapy in Farsi.

2.3.2. Language assessment (June 2009)

F.Gh. referred to us for linguistic assessment 18 months post-onset, on 11 June 2009. At that time she was unable to produce speech in Farsi and could only produce a limited number of incomprehensible words in Turkish. The Farsi and Turkish tests were given to her at the same day.

In spontaneous speech, F.Gh. was not able to produce any words. In these cases her responses were nonverbal such as head movements and pointing. Yet, her performance was relatively better in Turkish.

The patient's performance in Farsi pointing and simple and semi-complex commands tasks was very weak, yet better in Turkish. In neither of the languages could she perform complex tasks. She could only perform one of the three commands at a time in Turkish. Her verbal auditory discrimination was also impaired. In addition, she had some disorders in syntactic comprehension.

F.Gh. could not answer any of the questions in synonyms and antonyms tasks in both languages. In repetition task, most of her answers were wrong since she produced words with phonemic paraphasia. There were only few words which she could repeat without phonemic substitution or omission. In sentence repetition task in Farsi, she could not even repeat a word. However, in Turkish she could repeat sentences with paraphasia which made them incomprehensible.

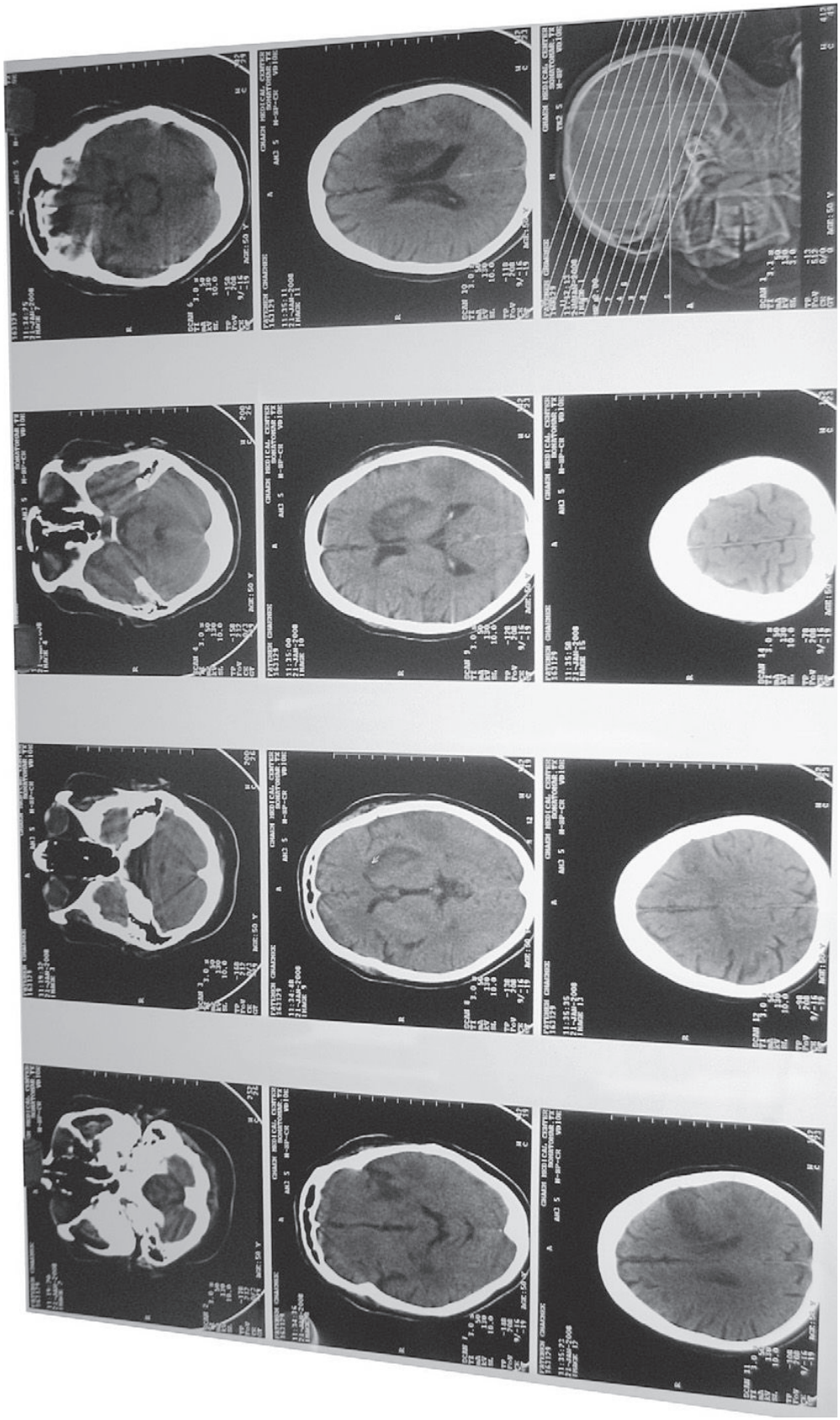

Fig. 3. CT scan of case 3 (F.Gh.). Lesion can be seen in the left striatocapsular area.

The patient could not produce series in Farsi but she was able to name three days of week with paraphasia and count to three in Turkish. Moreover she repeated every word she produced several times. She was not able to name anything in naming task in Farsi but she could name "pen" in Turkish and used this word to name other things in the task. She was unable to perform other tasks. She was aware of her disorders and cried whenever she could not express herself or perform the tasks.

According to the BAT results, this patient suffered from severe production disorders. Her comprehension and repetition were also impaired, although her production disorders were noticeably more severe. She had subcortical aphasia and her pattern of recovery was differential 17 months post-onset with Turkish as the best recovered language.

3. Discussion

The reported cases of subcortical bilingual aphasia are very rare and there is no other linguistic study of subcortical aphasia in Farsi and in Iran. On the other hand, since several variables are involved in these studies, the results are not definite. However, future studies on subcortical bilingual aphasic patients can add to the number of reported cases and help reach more definitive generalizations.

In this study, the linguistic behaviors of three bilingual right-handed adult patients (2 female, 1 male) with subcortical lesions have been assessed in order to determine the disorders in each of their languages and their patterns of recovery. All patients had subcortical aphasia resulting from left striatocapsular stroke. The time of language assessment was in their late phase and between 12 and 31 months post-onset.

All these patients could speak both languages fluently before the stroke and had learned the spoken type of languages before the written type of them.

Based on the BAT results, all three subcortical aphasics had the same pattern of recovery, namely differential. In all of them, the best recovered language was their mother tongue which was also the dominant language of their environment post-onset. Therefore, it is suggested based on these three patients that perhaps patients with left striatocapsular lesions would have differential pattern of recovery. E.M., the case studied by Aglioti had also differential pattern of recovery (Aglioti et al., 1996).

According to Kainz's theory (as cited in Fabbro, 2001b, p. 213) and Fabbro's hypothesis (Fabbro, 2001b) about the cortical and subcortical representation of languages, as a result of subcortical lesions, patient's first language should be more severely impaired and less recovered. In contrast, second language is expected to be less impaired and better recovered. However, in the cases reported in this paper, first language was less impaired than the second one and recovered better.

Therefore, according to our limited experience, it may be proposed that the subcortical organization of languages may be different in a bilingual brain. This difference might be due to the different ages of acquiring the first and the second languages. It is likely that the second language acquired at a higher age is represented more subcortically than the fist language. Although there exist a report of a case in which second language was the less impaired and the best recovered language (Aglioti et al., 1996). The age of the acquisition of second language was, though, not taken into account in that report.

Based on our experience, we suggest that, as the age of the acquisition of second language can affect the cortical organization of language, the differences observed in subcortical organization of languages can also be due to this factor. More studies on subcortical bilingual aphasics can test this hypothesis.

Since all three patients with subcortical aphasia had lesions in the left hemisphere, it might be concluded that perhaps in bilinguals, language is lateralized in subcortical areas as well as in cortex, and that this lateralization might be in the left hemisphere. Subcortical laterality of speech in left hemisphere has been first suggested for monolinguals by Hornickel et al. (Hornickel, Skoe, & Kraus, 2008).

Moreover, in these patients who had subcortical lesions in left striatocapsular area, speech production was more impaired than comprehension. It can be concluded that these subcortical structures are more involved in the production of speech rather than its comprehension in bilinguals. This was also observed in several studies on subcortical monolingual aphasics (particularly with striatocapsular lesions) in different languages (De Boissezon et al., 2005; Radanovic & Scaff, 2003).

4. Summary and conclusion

The aim of this paper has been to study the linguistic disorders, patterns of recovery and organization of languages in three Farsi-speaking bilingual aphasic patients who had striatocapsular strokes. We suggest, based on these three patients, that subcortical structures might have a more important role in speech production than comprehension and that the first language might have more subcortical representation than the second language. It is also likely that languages are lateralized in subcortical areas of the left hemisphere. Moreover, subcortical organization of languages might correlate with the age of acquisition of second language.

References

Aglioti, S., Beltramello, A., Girardi, F., & Fabbro, F. (1996). Neurolinguistic and follow-up study of an unusual pattern of recovery from bilingual subcortical aphasia. *Brain, 119*, 1551–1564.

Chung, C., Caplan, L. R., Yamamoto, Y., Chang, H. M., Lee, S. J., Song, H. J., et al. (2000). Striatocapsular haemorrhage. *Brain, 123*, 1850–1862.

De Boissezon, X., De'monet, J., Puel, M., Marie, N., Raboyeau, G., Albucher, J., et al. (2005). Subcortical aphasia: a longitudinal PET study. *Stroke, 36*, 1467–1473.

Fabbro, F. (2001a). The bilingual brain: bilingual aphasia. *Brain and Language, 79*, 201–210.

Fabbro, F. (2001b). The bilingual brain: cerebral representation of languages. *Brain and Language, 79*, 211–222.

Hornickel, J., Skoe, E., & Kraus, N. (2008). Subcortical laterality of speech encoding. *Audiology & Neurotology, 14*, 198–207.

Meinzer, M., Obleser, J., Flaisch, T., Eulitz, C., & Rockstroh, B. (2007). Recovery from aphasia as a function of language therapy in an early bilingual patient demonstrated by fMRI. *Neuropsychologia, 45*, 1247–1256.

Murdoch, B. E. (2004). Language disorders in adults: subcortical involvement. In R. D. Kent (Ed.), *The MIT encyclopedia of communication disorder* (pp. 314–318). Boston: MIT Press.

Obler, L. K., & Gjerlow, K. (2000). *Language and the brain*. Cambridge: CambridgeUniversity Press.

Paradis, M. (1987). *The assessment of bilingual aphasia*. London: Lawrence Erlbaum Associates.

Paradis, M. (2004). *A neurolinguistic theory of bilingualism*. Amsterdam: John Benjamins.

Porch, B. E., & de Berkeley-Wykes, J. (1985). Bilingual aphasia and its implications for cerebral organization and recovery. *Clinical Aphasiology Conference, 15*, 107–112.

Radanovic, M., & Scaff, M. (2003). Speech and language disturbances due to subcortical lesions. *Brain and Language, 84*, 337–352.