



Pathological Evaluation of Two Techniques of Amniotic Membrane Patching on Experimentally Induced Corneal Lesions in Dogs

Mohammad Abbaszadeh^{1*}, DVSc
Seyed Javid Aldavood², DVSc
Alireza Foroutan³, PhD
Seyed Hossein Mardjanmehr⁴, DVSc
Mohammad Azizzadeh⁵, DVSc
Mohammad Reza Emami⁵, DVSc
Sadra Izadi², DVM

¹*Department of Clinical Sciences, Faculty of Veterinary Medicine, University of Shiraz, Shiraz, Iran.*

²*Department of Clinical Sciences and* ⁴*Department of Pathology, Faculty of Veterinary Medicine, University of Tehran, Tehran, Iran.*

³*Department of Clinical Sciences, Eye Research Center, Iran university of Medical Sciences, Tehran, Iran.*

⁵*Department of Clinical Sciences, Faculty of Veterinary Medicine, Ferdowsi University, Mashhad, Iran.*

Abstract

Objective- This study was performed to evaluate and compare grossly and pathologically two surgical techniques of amniotic membrane patching on experimental corneal alkali burn in dogs.

Design- Experimental study.

Animals- Fifteen healthy dogs

Procedures- The central corneas of the dogs were inflicted by applying a round filter paper, 6.0 mm in diameter, soaked in 1 N NaOH for 60 sec. A corneal alkali burn was made unilaterally in each dog's eye. A total of fifteen dogs were divided into three groups of five each: (A) uncovered as a control group; (B) covered by amniotic membrane (AM) patching with the amnion cell side down sutured around the corneal wound area with 10/0 nylon as AM+suture group; (C) covered by sutureless amniotic membrane patch adhered by 2-Octyl cyanoacrylate (Dermabond[®]) as AM+glue group. Time of surgery and AM persistence were

* Corresponding author:

Mohammad Abbaszadeh, DVSc

Department of Clinical Sciences, Faculty of Veterinary Medicine, University of Shiraz, Shiraz, Iran.

E-mail address: vetmail@gmail.com

recorded. After 3 weeks eyes enucleated and Samples were monitored by evaluating of most important pathological features.

Results- The mean time of surgery in group B was significantly longer than group C. AM persistence in group C was significantly more than group B. Corneal thickness measurements and numbers of epithelial rows showed no significant statistical differences between different groups. Group C has had significant lower degree of corneal vascularization than group A. Stromal edema was most prominent in group A, but statistical analysis revealed no significant statistical differences between groups. Stromal collagen arrangement showed no significant differences. AM patched corneas (group B, C) show lower inflammation, compared with the uncovered one (group A). Among the AM patching groups, the group C revealed the best result.

Conclusion and Clinical Relevance- use of the sutureless amniotic membrane patching with 2-Octyl cyanoacrylate as a dressing on a corneal alkali burn could induce rapid epithelial healing with less inflammatory response as well as reduce the time of operation in dogs.

Key Words- Amniotic membrane, corneal alkali burn, Dermabond[®], 2-Octyl cyanoacrylate, Dog.

Introduction

An alkali burning of the cornea causes a recalcitrant keratitis characterized by frequent blister formation, recurrent epithelial breakdown, stromal cell death, inflammatory cell infiltration and endothelial dysfunction¹. Despite many clinical treatments being advocated, moderate and severe alkali burns remain difficult to treat and frequently lead to a protracted course with various sight-threatening complications.

Amniotic membrane (AM) contains no blood vessels or nerves; instead, the nutrients it requires are supplied directly by diffusion out of the amniotic fluid and/or from the underlining decidua. The innermost layer, nearest to the foetus, is called the amniotic epithelium and consists of a single layer of cells uniformly arranged on the basement membrane. The compact layer of stromal matrix adjacent to the basement membrane forms the main fibrous skeleton of the AM. The collagens of the compact layer are secreted by mesenchymal cells situated in the fibroblast layer. The intermediate layer (spongy layer or zona spongiosa) of the stromal matrix sits adjacent to the chorionic membrane. Its abundant contents of proteoglycans and glycoproteins produce a spongy appearance in histological preparations, and it contains a nonfibrillar meshwork of mostly type III collagen.²⁻⁴

Sorsby and Symons successfully promoted healing with the use of amniotic membrane as a patch for treating acute ocular burns for the first time.⁵ For unclear reasons, the use of amniotic membrane disappeared from the literature. Recently, several reports disclosed the use of AM in various ocular surface diseases such as neurotrophic keratitis, persistent epithelial defects, band keratopathy, bullous keratopathy, after excimer laser photorefractive keratectomy, after the excision of a conjunctival mass, pterygium, ocular surface reconstruction in symblepharon, acute chemical injury and chronic limbal deficiency.^{3,6-8}

Since Kim and Tseng reported the effectiveness of AM transplantation in an experimental alkali burn model,³ many clinical reports have been published in regard to this treatment.⁹⁻¹⁵ In those reports, two ways of AM transplantation were demonstrated, graft and patch. The main purpose of the patch seems to enhance epithelial healing of the damaged cornea. On the other hand, an AM patch applied over an excimer laser-ablated cornea has been shown not only to enhance epithelial healing but also to reduce corneal haze.^{16,17}

The most common current method of attaching AM is by means of suturing. The use of sutures requires a high surgical skill and is associated with several disadvantages, including prolonged operating time and suture-related complications, such as suture abscesses, granuloma formation, and tissue necrosis.^{9,18-21} Moreover, corneal irritation, scarring, graft loss due to membrane shrinkage, the need for subsequent suture removal, postoperative pain and discomfort due to foreign body sensation and tearing of reconstructed ocular surface are significant problem for patients.²² Replacement of sutures with bioadhesives might be an advantageous alternative. The synthetic adhesives were used as substitutes for conventional sutures. Cyanoacrylate is an adhesive that results from the chemical reaction between formaldehyde and the esters of cyanoacetate. These products have been used in plastic surgery, gastrointestinal tract surgery and in oral and maxillofacial surgery. They have also been applied in kidney, liver and bone lesions and on animal and human blood vessels.²³⁻²⁵

cyanoacrylate enhances skin wound healing by reducing inflammatory response and prevents collagenase production.²⁶⁻³⁰

Cyanoacrylate glues have been successfully applied in ophthalmology to repair corneal perforations.²⁸ Watte et al. used butyl-2-cyanoacrylate adhesive in the management of canine and feline corneal diseases, such as conjunctival grafts.³⁰ Different types of cyanoacrylate adhesive have been used in surgery.³¹ Dermabond® (2-octylcyanoacrylate), is much more pliable and tissue compatible than its predecessors. It is less toxic and almost four times stronger than N-butyl-2-cyanoacrylate. In 2001, Taravella and Chang reported the successful use of 2-octyl cyanoacrylate to seal a corneal perforation.³²

The aim of this study was pathological evaluation of the use of suture or 2-Octyl cyanoacrylate to adhere amniotic membrane patch in treatment of experimental corneal alkali burn in dogs.

Materials and Methods

All experimental procedures in this study were performed simultaneously and were also approved by Iranian laboratory animal ethic framework and under supervision of Iran SPCA. Fifteen mixed-breed adult male and female dogs with normal eyes, weighting about 15 Kg and 1-2 years old were divided equally into three groups. Prior to the study, complete physical examinations, complete blood counts (CBC) and ophthalmic examinations including, slit lamp biomicroscopy, STT and fluorescein staining of both eyes were performed.

Animals were anesthetized by acepromazine (0.1 mg/kg, IM), diazepam (0.2 mg/kg, IV) and ketamine (10 mg/kg, IV). The procedure of corneal alkali burning was done by placing a 6-mm-diameter circular piece of filter paper soaked in 1 NaOH on the central cornea for 60s. Burning was done unilaterally in right dog's eye. Then, the cornea was rinsed by 2 ml of physiological saline immediately after alkali exposure. No treatment was performed for group A as a control group. In group B human amniotic membrane (AmniDress®, Imen Chemi Narin Ltd Co, Tehran, Iran.) was placed over the wound with the basement membrane side facing down, and sutured around the corneal wound area in a single interrupted pattern using 10/0 nylon suture (fig. 1). In group C, the AM was attached (basement membrane side down) by using of 2-Octyl Cyanoacrylate (Dermabond®, Ethicon, Somerville, New Jersey) (fig. 2). In the post-operative period, dogs received ciprofloxacin eye drops 4 times daily on the corneal wounds. The operation time were recorded. The eyes were examined daily for 21 days and duration of AM persistence (days) was monitored.

The corneal burns were examined and photographed after staining by 2% fluorescent stain once daily (after falling of AM). After that (day 22), all dogs were anesthetized and right eyes were enucleated. Eyes were fixed in 10% buffered formalin and embedded in paraffin. Sections were stained with H & E, PAS and Gram and examined by light microscopy (Olympus BX41, Japan). To document the findings, microphotographs were obtained by digital camera (Olympus DP12, Japan). Samples were monitored by evaluating of corneal thickness (μm), numbers of epithelial rows, stromal vascularization, inflammation, edema and collagen arrangement. The severity of stromal edema was graded 0-3 by a masked investigator³³ (table 1). Stromal vascularization were graded 0 to 3 by mean of number of blood vessels in 10 microscopic field in lens magnification: 20. Inflammation grading was based on presence and inflammatory cells (table 1). Normal and abnormal stromal collagen arrangements were graded respectively 0 and 1. Statistical analysis was performed by Kruskal–Wallis test. Pairwise comparison between groups was performed. P values less than 0.05 were considered to be significant.

Table 1. Grading of stromal edema and inflammation.

Grading of stromal edema		Grading of stromal inflammation based on presence, counting and scattering of inflammatory cells	
Grade 0	completely clear cornea	Grade 0	No inflammatory cell
Grade 1	focal exudation in stroma	Grade 1	Scattered and few in number
Grade 2	increase in stromal thickness	Grade 2	less than nucleus count of keratocyte
Grade 3	sever increase in stromal thickness and exudation	Grade 3	More than nucleus count of keratocyte

Results

Analysis of mean operation time in groups B (AM+suture) and C (AM+glue) was performed. The mean operation time in group B was significantly longer than group C ($P < 0.001$). AM persistence in group C was significantly longer than group B ($P = 0.023$). AM rejection occurred faster in group B in comparison to group C.

H&E and PAS staining revealed that no eyes were perforated and that descemet's membrane and endothelium were normal in all 15 eyes. Corneal thickness measurement in different groups showed no significant statistical differences. Also, numbers of epithelial rows revealed no significant differences ($P > 0.05$) (table 2).

Some degree of increased Keratocyte density and fibroblast differentiation were seen in all corneas.

Corneal vascularization revealed significant differences between groups. Pairwise comparison indicated group C has had significant lower degree of corneal vascularization than group A (fig. 3 and 6) ($P = 0.15$) (table 2).

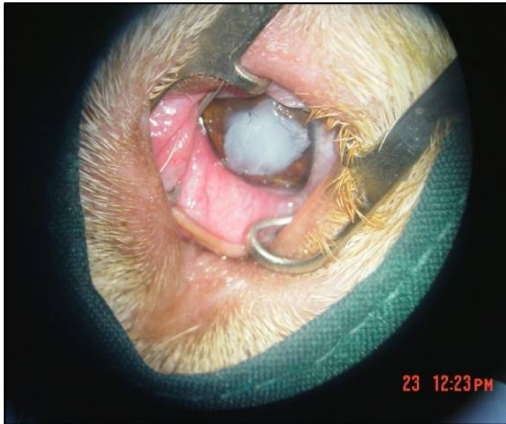


Figure 1. The dog's eye in group A. Human amniotic membrane was placed on the corneal ulcer with the basement membrane side facing down, and sutured around the corneal wound area in a single interrupted pattern using 10/0 nylon sutures.

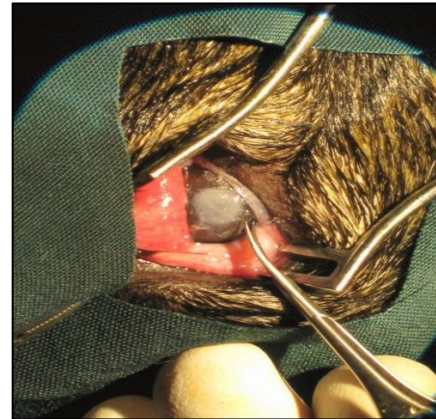


Figure 2. The dog's eye in group C. Sutureless attachment of AM (basement membrane side down) on corneal chemical burn by using of 2-Octyl Cyanoacrylate (dermabond®).

Table 2. Quantitative data of corneal thickness, rows of epithelium, vascularization, inflammation and edema in all corneas.

	PCT (μm)	Epithelium (row)	Vascularization (0-3)	Inflammation (0-3)	Edema (0-3)
Group A	1000	3-7 row	3	2	3
Group A	1100	6-10 row	3	3	3
Group A	900	6-9 row	3	2	2
Group A	1000	6-10 row	3	3	3
Group A	800	6-8 row	2	2	2
Group B	650	6-10 row	2	2	0
Group B	800	4-9 row	3	2	2
Group B	600	4-8 row	3	1	1
Group B	1000	6-9 row	2	2	2
Group B	900	6-8 row	2	1	1
Group C	750	(focally degenerate)	0	1	1
Group C	1000	9-11 row	2	2	3
Group C	1200	11-20 row	2	1	3
Group C	800	4-6 row	1	1	0
Group C	800	4-8 row	1	1	1

Some degree of inflammation were seen in all corneas, but groups of AM patched ones showed lower inflammation, compared with group A (table 2). Among the AM patching groups, the group C revealed the significant lower inflammation compared with group A (fig. 7) ($P=0.024$). Between two AM patching groups, PMN and granulomatous inflammation was more in group B. PAS and gram staining showed no bacterial or fungal infection in all corneas.

Stromal edema was most prominent in control group, but statistical analysis revealed no significant statistical differences between groups ($P>0.05$) (table 2). Stromal collagen arrangement was not completely normal in any group (fig. 5) and in all groups considered abnormal, so showed no significant differences ($P>0.05$).

Suture thread was presented in 4 corneas of group B. polymorphonuclear and mononuclear cells were more around the site of the suture point in comparison to other sites of stroma (fig. 4). Lipid kerathopathy adjacent to the capillaries was seen in stroma of 7 corneal samples (3 cases of control group, 2 stroma of group B and 2 stroma of group C) (fig. 3).

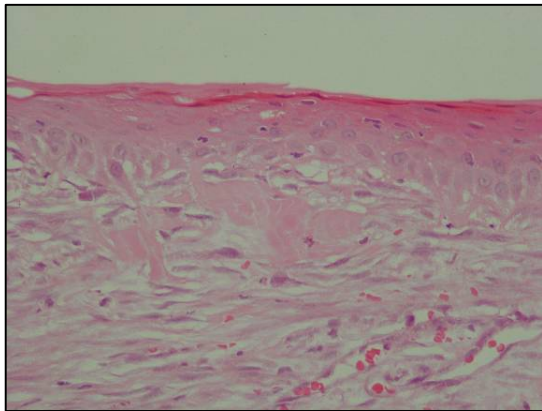


Figure 3. Photomicrographs of cornea from dog in group A. Inflammatory cell, exudation, vascularization (arrow) and Lipid keratopathy (adjacent to the capillary) can be visualized. (HE×400).

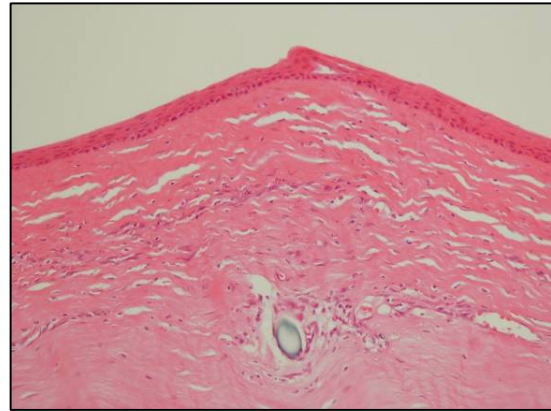


Figure 4. Photomicrographs of cornea from dog in group B. The epithelium already is formed with incomplete organization of the stroma. presence of the suture thread (arrow) and polymorphonuclear and mononuclear cell around the site of the suture point. (HE×200).

Discussion

The repair of the severely ulcerated cornea is a challenge for ophthalmologists. Alkali burns are the most serious of chemical injuries of the anterior segment of the eye.¹⁴ Several methods of correction and materials have been described in the last few years for corneal defects.^{3,6,9-17,30,34}

Lack of reports on effects of sutureless amniotic membrane patching on corneal alkali burn healing with 2-Octyl cyanoacrylate (Dermabond®) in dogs, encouraged us to perform present investigation. The study reported here allowed us to evaluate and compare pathological feature of suturing of AM with sutureless AM patching with 2-octyl cyanoacrylate adhesive on corneal alkali burn wounds in dogs.

The mean operation time in group B was significantly longer than group A ($P < 0.001$). This could explain that using sutureless amniotic membrane patching on corneal alkali burn can reduce anesthetic complications. The results of present study showed that the AM persistence on cornea in group C was significantly longer than group B. As the amniotic membrane has anti protease activity and facilitates epithelialization and reduces vascularization and scarring on corneal ulcer,^{3,4,34} it is assumed that longer remaining of AM (delay in graft rejection) has more positive effect to facilitate treatment of corneal ulcers in affected animals.

Kim et al. used AM patching on corneal alkali burn and showed AM-covered groups formed thicker cornea than the uncovered group initially at 1 week, but after 4 weeks they showed a thinner cornea than the control group. They suggest AM coverage inhibited evaporation from the wound site in the initial stage, but later the thickness was reduced to normal around 8 weeks by enhancement of wound healing, including recovery of endothelial cell function.¹² In our study, Corneal thickness measurement and numbers of epithelial rows in different groups showed no significant statistical differences after 3 week ($P > 0.05$).

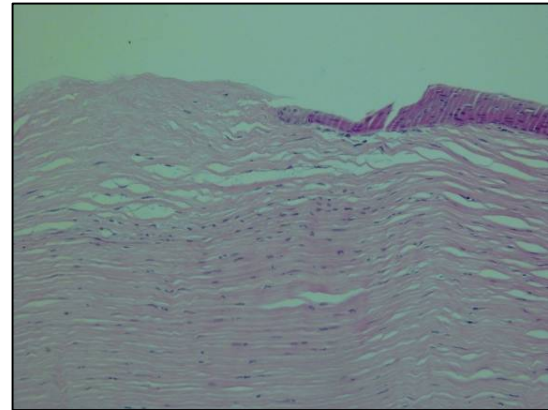


Figure 5. Photomicrographs of cornea from dog in group C. Mild disarrangement of stroma. No vascularization. (HE×200).

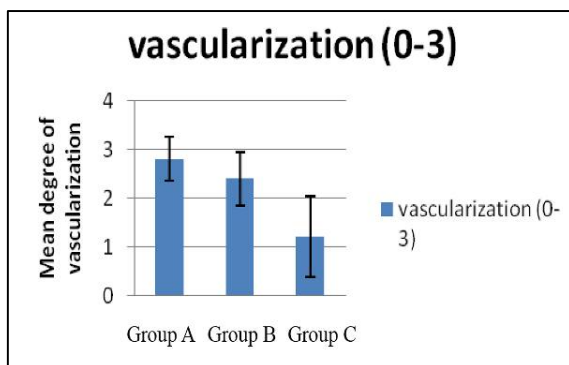


Figure 6. The graph demonstrates the mean degree of vascularization. Group C had significant lower degree of corneal vascularization than group A ($p < 0.05$).

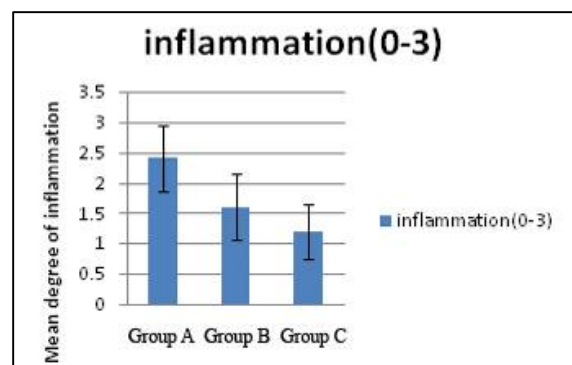


Figure 7. The graph demonstrates the mean degree of inflammation. The groups B, C showed lower inflammation, in compared with control group. Among the AM patching groups, group C revealed the best result ($p < 0.05$).

The corneal opacity is related to edema due to water capture and disarrangement of the normal pattern of collagen lamellas of the stroma and is very common in alkali burn cornea.³⁵ These opacities were stromal changes in the cornea caused by alkali damage. AM alone does not remove corneal opacities.³⁶ In the present study, the opacity was most prominent in control group, but there were no significant statistical differences between groups ($P > 0.05$). Although, stromal collagen arrangement was not completely normal in the groups showed no significant differences ($P > 0.05$). Neovascularization was observed in all groups except one dog in group 3

and it was more in group A than other groups. The dogs in group C had a significant lower degree of corneal vascularization than group A. The corneal vascular neof ormation appears due to persistent, infected or destructive stromal lesions in order to improve the tropism of the injured site and to carry inflammatory mediators.³⁷ Lee and Tseng showed the efficacy of amniotic membrane patch in improvement of corneal epithelial defect and the probability of attribution of AM in inhibition of collagenase and in supplementation of the basement membrane and growth factors.⁶ Some investigators identified antiangiogenic and anti-inflammatory proteins in human amniotic membrane.³⁸ In present study, it is assumed that combination of these factors with use of sutureless AM patching technique with 2-octyl cyanoacrylate helped rapid healing and reduction of corneal vascularization. The little neovascularization and inflammation in group C suggests that a rapid organization of the corneal stroma has occurred in the absence of infection, and consecutively without need of inflammatory mediators.

Some degree of inflammation were seen in all corneas, but the AM patching groups show lower inflammation, compared with the control group. Among the AM patching groups, the sutureless AM patching group with dermabond[®] revealed the best result. There are several reports that AM reduces inflammation.¹² The AM stromal matrix markedly suppresses the expression of the potent pro-inflammatory cytokines, IL-1 α and IL-1 β .³⁹ Matrix metalloproteases (MMPs) are expressed by infiltrating polymorphonuclear cells and macrophages. Natural inhibitors of MMPs have been found in AM.^{12,38} The β 3-defensin (anti-microbial peptides) is the predominant defensin in the amniotic epithelial.⁴⁰ In addition, two low-molecular-mass elastase inhibitors, secretory leukocyte proteinase inhibitor (SLPI) and elafin, are expressed in AM.^{40,41} In addition to their anti-inflammatory properties, elafin and SLPI both have antimicrobial actions.⁴² Because AM has anti-microbial and anti-inflammatory effects, both AM patching groups in our research had better results than control group.

In this study, infiltrations of polymorphonuclear and mononuclear cell were more (in comparison with other sites of stroma) around the site of the suture point in group B (fig. 4). Suture may induce inflammatory reaction, granuloma formation and tissue necrosis.¹⁹ On the other hand, cyanoacrylate enhances skin wound healing by decrease of inflammatory response,^{26,27} prevents collagenase production^{27,29} and has bacteriostatic properties.²⁷ It's probably the reasons that group C had less inflammation and vascularization than group B and significant less inflammation and vascularization than group A.

One of corneas in group C had deep stromal vascularization and grade 3 (severe) edema. The cause of these pathological signs of this dog can be attributed to several factors. Despite that the 2-octyl cyanoacrylate have longer chain, thus degrades slower and may result in lower concentrations of the cyanoacrylate products in tissues and generate less inflammation and are less toxic than the methyl-2-cyanoacrylate used in the past, the major concern is toxicity of cyanoacrylate through direct contact with the corneal endothelium and lens.⁴³

In this study, because of keeping sterility during creating corneal ulcer, PAS and gram staining showed no bacterial or fungal infection in all corneas. Also as mentioned above, AM and 2-octyl cyanoacrylate could have bacteriostatic properties.^{27,42}

In this study, AM+glue group has some advantages that are less time consuming sutureless technique in compare to AM+suture group and less corneal vascularization and less inflammation in compare with control group. All these results indicate that use of AM suturless patching with dermabond[®] (2-octyl cyanoacrylate) adhesive offers the clinicians a less disturbant, fast and effective method for corneal wounds without need of high degree of surgical

skill, of long operating time and of suture-related complications. So, it should be recommended as a superior option in treatment of alkali corneal burn.

References

1. McCulley JP. Chemical agents. In *The Cornea*. 1994; 617-33.
2. Parry S, Strauss JF. Premature rupture of the fetal membranes. *N Engl J Med* 1998; 338: 663-670.
3. Kim JC, Tseng SCG. Transplantation of preserved human amniotic membrane for surface reconstruction in severely damaged rabbit corneas. *Cornea* 1995; 14: 473-484.
4. Kurpakus MA, Stock EI, Jones JCR. The role of the basement membrane in different expression of keratin proteins in epithelial cells. *Dev Biol* 1992; 150: 243-255.
5. Sorsby A, Symons HM. Amniotic membrane grafts in caustic burns of the eye. *Br J Ophthalmol* 1992; 30: 337-345.
6. Lee S, Tseng SCG. Amniotic membrane transplantation for persistent epithelial defects with ulceration. *Am J Ophthalmol* 1996; 123: 303-312.
7. Park JH, Jeoung JW, Wee WR, Lee JH, Kim MK. Clinical efficacy of amniotic membrane transplantation in the treatment of various ocular surface diseases. *Contact Lens and Anterior Eye* 2008; 31: 73-80.
8. Tsubota K, Satake Y, Ohyama M, et al. Surgical reconstruction of the ocular surface in advanced ocular cicatricial pemphigoid and Stevens-Johnson syndrome. *Am J Ophthalmol* 1996; 122: 38-52.
9. Chen HJ, Pires RT, Tseng SC. Amniotic membrane transplantation for severe neurotrophic corneal ulcers. *Br J Ophthalmol* 2000; 84: 826-833.
10. Hanada K, Shimazaki J, Shimmura S. Multilayered amniotic membrane transplantation for severe ulceration of the cornea and sclera. *Am J Ophthalmol* 2001; 131: 324-331.
11. Honavar SG, Bansal AK, Sangwan VS. Amniotic membrane transplantation for ocular surface reconstruction in Stevens-Johnson syndrome. *Ophthalmology* 2000; 107:975-979.
12. Kim JS, Kim JC, Na KB, et al. Amniotic Membrane Patching Promotes Healing and Inhibits Proteinase Activity on Wound Healing Following Acute Corneal Alkali Burn. *Exp Eye Res* 2000; 70: 329-337.
13. Kruse FE, Rohrschneider K, Volcker HE. Multilayer amniotic membrane transplantation for reconstruction of deep corneal ulcers. *Ophthalmology* 1999; 106: 1504-1510.
14. Meller D, Pires RT, Mack RJ. Amniotic membrane transplantation for acute chemical or thermal burns. *Ophthalmology* 2000; 107: 980-989.
15. Tsai RJ, Li LM, Chen JK. Reconstruction of damaged corneas by transplantation of autologous limbal epithelial cells. *N Engl J Med* 2000; 343: 86-93.
16. Wang MX, Gray TB, Park WC. Reduction in corneal haze and apoptosis by amniotic membrane matrix in excimer laser photoablation in rabbits. *J Cataract Refract Surg* 2001; 27: 310-319.

17. Woo HM, Kim MS, Kweon OK. Effects of amniotic membrane on epithelial wound healing and stromal remodelling after excimer laser keratectomy in rabbit cornea. *Br J Ophthalmol* 2001; 85: 345–349.
18. Chen PP, Ariyasu RG, Kaza V. A randomized trial comparing mitomycin C and conjunctival autograft after excision of primary pterygium. *Am J Ophthalmol* 1995; 120: 151–160.
19. Koranyi G, Seregard S, Kopp ED. Cut and paste: a no suture, small incision approach to pterygium surgery. *Br J Ophthalmol* 2004; 88: 911–914.
20. Sridhar MS, Bansal AK, Rao GN. Surgically induced necrotizing scleritis after pterygium excision and conjunctival autograft. *Cornea* 2002; 21: 305–307.
21. Ti SE, Chee SP, Dear KB, et al. Analysis of variation in success rates in conjunctival autografting for primary and recurrent pterygium. *Br J Ophthalmol* 2000; 84: 385–389.
22. Uy HS, Reyes JM, Flores JD, et al. Comparison of fibrin glue and sutures for attaching conjunctival autografts after pterygium excision. *Ophthalmology* 2005; 112: 667–671.
23. Singer AJ, Thode HC. A review of the literature on octylcyanoacrylate tissue adhesive. *Am J Surg* 2004; 187(2): 238-248.
24. Toriumi DM, O'Grady K, Desai D, et al. Use of octyl-2-cyanoacrylate for skin closure in facial plastic surgery. *Plast Reconstr Surg* 1998; 102: 209-219.
25. Vote JT, Elder MJ. Cyanoacrylate Glue for Corneal Perforations: A Description of surgical Technique and a Review of the Literature. *Clin Experiment Ophthalmol* 2000; 28(6): 437–442.
26. Bhaskar SN, Cutright DE. Healing of skin wound with butyl cyanoacrylate. *J Dent Res* 1969; 48(2): 294-297.
27. Eriksson L. Cyanoacrylate for closure of wound in the mucosa in dogs. *Odontol Revy* 1976; 27(1): 19-24.
28. De Almeida Manzano RP, Naufal SC, Hida RY, et al. Antibacterial analysis in vitro of ethyl-cyano-acrylate against ocular pathogens. *Cornea* 2006; 25(3): 350–351.
29. Eiferman RA, Snyder JW. Antibacterial effect of cyanoacrylate glue. *Arch Ophthalmol* 1983; 101(6): 958–960.
30. Watte M, Elks R, Moore D, et al. Clinical experience with butyl-2-cyanoacrylate adhesive in the management of canine and feline corneal disease. *Vet Ophthalmol* 2004; 7(5): 319-326.
31. Lauto A, Mawad D, Foster L. Review Adhesive biomaterials for tissue reconstruction. *J Chem Technol Biotechnol* 2008; 83: 464–472.
32. Taravella MJ, Chang CD. 2-Octyl cyanoacrylate medical adhesive in treatment of a corneal perforation. *Cornea* 2001; 140(20): 220 –221.
33. Pfister RR, Pfister DA. Alkali-injuries of the eye. In *Cornea* 1997. 1443-1451.
34. Shimazaki J, Yang HY, Tsubota K. Amniotic membrane transplantation for ocular surface reconstruction in patients with chemical and thermal burns. *Ophthalmology* 1997; 104: 2068–2076.
35. Waring GO. Corneal structure and pathophysiology. In: Leibowitz HWB, eds. *Corneal Disorders: Clinical Diagnosis and Management*. Philadelphia: WB Saunders Co, 1984. 3-25.

36. Kozak, Trbolova A, Sevcikova Z, et al. Superficial keratectomy, limbal Autotransplantation and amniotic membrane transplantation in the treatment of severe chemical burns of the eye. *Acta Vet Brno* 2002; 71: 85-91.
37. Morales A, Laus JL, Souza MSB, et al. Comparação entre enxertos autógenos livres e pediculados de conjuntiva no reparo de ceratectomias superficiais. Estudo experimental no cão. *Braz J Vet Ani Sci* 1996; 33: 28-31.
38. Hao Y, Ma DHK, Hwang DG. identification of antiangiogenic and anti inflammatory proteins in human amniotic membrane. *Cornea* 2000; 19: 348-352.
39. Solomon A, Rosenblatt M, Monroy D, et al. Suppression of interleukin-1 alpha and interleukin-1 beta in human limbal epithelial cells cultured on the amniotic membrane stromal matrix. *Br J Ophthalmol* 2001; 85: 444-449.
40. Buhimschi IA, Jabr M, Buhimschi CS, et al. The novel antimicrobial peptide beta3-defensin is produced by the amnion: a possible role of the fetal membranes in innate immunity of the amniotic cavity. *Am J Obstet Gynecol* 2004; 191: 1678-1687.
41. Kim JS, Kim JC, Na BK, et al. Amniotic membrane patching promotes healing and inhibits proteinase activity on wound healing following acute corneal alkali burn. *Exp Eye Res* 2000; 70: 329-337.
42. King AE, Critchley HO, Sallenave JM, et al. Elafin in human endometrium: an antiprotease and antimicrobial molecule expressed during menstruation. *J Clin Endocrinol Metab* 2003; 88: 4426-4431.
43. Toriumi DM, Raslan WF, Friedman M, et al. Histotoxicity of cyanoacrylate tissue adhesives: a comparative study. *Arch Otolaryngol Head Neck Surg* 1990; 116: 546-550.

ارزیابی آسیب شناسی دو روش استفاده از وصله پرده آمیوتیک در درمان زخم های قلیایی قرنیه در سگ

محمد عباس زاده^۱، سید جاوید آل داوود^۲، علیرضا فروتن^۳، سید حسین مرجانمهر^۴،
محمد عزیز زاده^۵، محمد رضا امامی^۵، سدر ایزدی^۲

^۱ گروه علوم درمانگاهی، دانشکده دامپزشکی دانشگاه شیراز، شیراز، ایران.

^۲ گروه علوم درمانگاهی، و ^۴ گروه پاتولوژی دانشکده دامپزشکی دانشگاه تهران، تهران، ایران.

^۳ مرکز تحقیقات چشم، دانشگاه علوم پزشکی ایران، تهران، ایران.

^۵ گروه علوم درمانگاهی، دانشکده دامپزشکی دانشگاه فردوسی مشهد، مشهد، ایران.

هدف - این تحقیق در جهت ارزیابی و مقایسه دو روش استفاده از پوشش پرده آمیوتیکی (بوسیله بخیه و روش دیگر بدون بخیه) در درمان زخم های قلیایی قرنیه انجام پذیرفت.

طرح مطالعه - مطالعه تجربی.

حیوانات - پانزده قلاده سگ.

روش کار - پانزده قلاده سگ با قرنیه های سالم در ۳ گروه ۵ تایی تقسیم شدند. در چشم راست همه سگ ها، زخم قرنیه به شرح زیر ایجاد شد: با استفاده از کاغذ صافی به قطر ۶ میلی متر که به طور یکسان با سود یک نرمال آغشته بود و به مدت ۶۰ ثانیه در مرکز قرنیه قرار داده شد. گروه ۱: کنترل (عدم وجود پوشش قرنیه)، گروه ۲: استفاده از پوشش پرده آمیوتیک طوری که سلول های آمیونونی به طرف پایین باشد، با بخیه اطراف زخم و گروه ۳: استفاده از پوشش آمیونونی (بدون بخیه) و اتصال بوسیله چسب ۲-اکتیل-سیانوآکریلات. زمان جراحی و تعداد روزهای بقاء پوشش آمیوتیکی روی چشم ها مقایسه شد. بعد از روز ۲۱، قرنیه ها جهت بررسی پاتولوژی برداشت شد.

نتیجه گیری و کاربرد بالینی - متوسط زمان جراحی در گروه ۳ نسبت به گروه ۲ به طور معنی داری کمتر بود. تعداد روز ماندگاری پوشش آمیوتیکی در گروه ۳ نیز بیشتر از گروه ۲ مشاهده شد. در بررسی هیستوپاتولوژی، محاسبه قطر قرنیه و تعداد ردیف های اپیتلیوم معنی دار نبود. قرنیه های گروه ۳، به طور معنی داری عروق زایی کمتری را نسبت به گروه کنترل نشان داد. میزان نظم کلاژن های استروما در هیچ نمونه ای طبیعی نبود و اگرچه ادم در گروه کنترل بیشتر بود ولی این میزان معنی دار نبود. میزان التهاب در گروه ۳ نسبت به کنترل به طور معنی داری کمتر بود.

در نتیجه، استفاده از روش بدون بخیه پوشش آمیوتیکی (با استفاده از چسب ۲-اکتیل-سیانوآکریلات) در اینگونه زخم های قرنیه، ممکن است روشی ساده، موثر و با عروق زایی و التهاب کمتر باشد.

کلید واژگان - پرده آمیوتیک، زخم های قلیایی قرنیه، ۲-اکتیل-سیانوآکریلات، سگ.