Comparative Clinical Pathology (2018) 27:539–543
https://doi.org/10.1007/s00580-018-2643-3

CASE REPORT

Clinical and pathological findings of enzootic nasal adenocarcinoma of goat

Abdolrasoul Namjou[1] · Sadegh Shirian[2,3] · Iraj Karimi[2] · Hossein Nourani[4] · Mahdi Farid[5]

Received: 16 April 2017 / Accepted: 9 January 2018 / Published online: 18 January 2018

Abstract

The enzootic nasal tumor (ENT), a contagious tumor, is raised from the secretory epithelial cells of the ethmoid turbinate in animal which is caused by ENT virus type (ENTV) 2. The aim of this study is to investigate the clinical, radiological, and histopathological features of ENT or nasal adenocarcinoma in Lori-Bakhtiari breeds of goat. The affected goats showed respiratory nasal problems, continuous nasal exudate, and death resulted from progressive respiratory distress and anorexia. Dorsomedial radiographs of the skull region showed the mass in the right caudal paranasal sinus region deformation of bone in the near ethmoidal part. At necropsy, after dissection of the cranium through sagittal dorsomedial section, the presences of large unilateral tumor sessile masses with white, shiny, and soft like a gelatin form appearances were found. Acinar and papillary patterns were the most common histopathological finding in proliferated glands. The neoplastic cells were cuboidal or columnar with round or oval nuclei with very low mitotic index. This type of carcinoma originates from the serous gland cells in ethmoidal turbinate.

Keywords Enzootic nasal adenocarcinoma · Goat · Histopathology · Iran · Nasal cavity · Radiology

Introduction

Respiratory diseases of sheep and goats have contributed to 5.6% of the total diseases of small ruminants (Hindson and Winter 2002; Chakraborty et al. 2014). A major region of the respiratory system that is directly exposed to infection is the nasal cavity (Lopez 2012). Various types of tumors including squamous cell carcinomas, nasal polyps (adenopapillomas), lymphosarcomas, adenocarcinomas, and adenomas in the upper respiratory tracts of sheep and goats have been reported (Chakraborty et al. 2014). These tumors are mostly occurred in older animals (Lopez 2012). Enzootic nasal tumor virus is responsible for occurrence of enzootic nasal tumor, adenocarcinoma, and infectious nasal adenopapillomatosis in sheep and goats (MacLachlan and Dubovi 2011). Enzootic nasal adenocarcinoma (ENA) is a chronic and contagious viral disease of sheep, cattle, pigs, horses, and buffaloes (Wilson and Dungworth 2002; De las Heras et al. 2003) and has been less frequently reported (De las Heras et al. 1991) in goats (Scocco et al. 2001) which results in economic losses. In recent years, few goats with ENA have been documented in several countries such as Italy (Vitellozzi et al. 1993), Spain (Cousens et al. 1996; De las Heras et al. 2003), India (Rajan et al. 1980), China (Yi et al. 2010), and Turkey (Ozmen et al. 2010). Only Australia and New Zealand are considered to be completely free of the disease (De las Heras et al. 1991).

ENA originates from the underlying mucoserous glands, with the majority of cases occurring from the serous gland epithelial cells in the ethmoid turbinate region of the upper respiratory tract (Ortin et al. 2003), and often expands to occlude the nasal cavity (Walsh et al. 2013). ENA is caused by retrovirus, which is closely related to the jaagsiekte sheep retrovirus (JSRV) or sheep pulmonary adenomatosis (Yu et al. 2011) (more than 95% overall amino acid similarity) (Dirks et al. 2002), which causes neoplastic lesions in the

✉ Abdolrasoul Namjou
ar.namjo72@gmail.com

[1] Department of Pathobiology, Faculty of Veterinary Medicine, Shahrekord Branch, Islamic Azad University, Shahrekord, Iran

[2] Department of Pathology, School of Veterinary Medicine, Shahrekord University, Shahrekord, Iran

[3] Shiraz Molecular Pathology Research Center, Dr Daneshbod Pathology Lab, Shiraz, Iran

[4] Department of Pathobiology, Faculty of Veterinary Medicine, Ferdowsi University of Mashhad, Mashhad, Iran

[5] Department of Clinical Sciences, Faculty of Veterinary Medicine, Shahrekord Branch, Islamic Azad University, Shahrekord, Iran

lower respiratory system (Svara et al. 2006). Infection with the ENTV, an oncogenic retrovirus, induces unilateral or bilateral neoplastic transformation in the mucosal nasal glands of the ethmoid turbinate (Aydogan et al. 2013). It has been shown that the ENT etiology of sheep is mainly different from that of goat (De las Heras et al. 2003). ENT can be transmitted horizontally as well as inhalation of nasal discharge of naturally infected sheep and goats (De las Heras et al. 1995). The ENTs are all low-grade adenocarcinomas, which are sometimes locally invasive without metastatic behavior (Cousens et al. 1996); however, involvement of the nasal septum structure and the cribriform plate has been also reported (Walsh et al. 2013; Walsh et al. 2010). Clinically, ENA is characterized by persistent seromucosal nasal discharge and open mouth breathing accompanied by snoring, coughing, wheezing, and dyspnea (De las Heras et al. 1991). The duration of the ENT, from onset of clinical signs to death, varies from 3 weeks to 1 year or more (De las Heras et al. 1995).

In this paper, we describe the clinical, radiographical, gross histopathological features of ENA in naturally affected goats from the Ardal City in Chaharmahal and Bakhtiari Province of Iran. To the best of our knowledge, there are no prior reports of enzootic nasal tumors in goats in Iran.

Case report

Chaharmahal and Bakhtiari Province is situated in south-west of Iran. This province has a total area of 16,533 km^2 and its geographical latitude is 31° 4′ to 42° 4′ N; its longitude is 49° 39′ to 51° 21′ E and it has considerable sheep and goat populations. In this descriptive investigation undertaken in August 2016, a 6-year-old female Lori-Bakhtiyari goat from a single herd numbering 350 animals with weighed approximately 35 kg was studied. It has a history of persistent seromucosal nasal discharge leading to a "washed nose" appearance with depigmentation and alopecia occurring around the nostrils and open mouth breathing, accompanied by snoring, coughing, wheezing, and dyspnea prior to death (Fig. 1). No nervous signs were referenced for diagnosis of the disease.

Clinically, nasal problems, dyspnea, and seromucous nasal discharge were observed in 5% of the goats ranging in age from 1 to 9 years. Livestock owners reported that six goats died with relatively common problems in a 3-month period. Skull radiography was conducted on the goat head. Animal was humanely euthanized 3 months after appearance of clinical signs for necropsy and a histological examination was performed. The tissue samples were fixed in a 10% neutral buffered formalin fixative. Selected sections were processed routinely in an automatic tissue processor, embedded in paraffin, sectioned at 5 μm, stained with hematoxylin and eosin, and studied under light microscope (Olympus, Japan).



Fig. 1 A 6-year-old goat with a continuous unilateral seromucous nasal discharge

The female goat was examined at necropsy and observed typical mucoid in the right cornea diverticulum of frontal sinus of goat (Fig. 2).

Radiographs demonstrated an apparent mass in the caudal nasal cavity and maxillary sinus region with extensive deformation of bone in the nasal sinus region (Fig. 3) compared to healthy

Fig. 2 Typical mucoid in right corneal diverticulum of frontal sinus of goat (arrow)

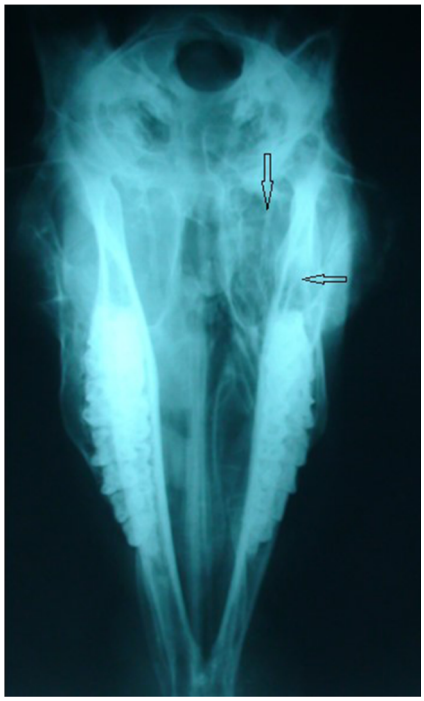

Fig. 3 Radiographs demonstrated an apparently mass in the right caudal paranasal nasal sinus region with extensive deformation of bone and opacity in the ethmoidal region (arrow)

one (Fig. 4). The typical postmortem findings in the sagittal sections of the skull showed a mass in the ethmoidal area of the caudal nasal cavity, unilateral, ranging 3 cm × 5 cm × 2 cm in diameter (Fig. 5). The mass appeared polypoid, sessile, white in color, gelatinous with a friable consistency, and a granular surface covered by watery, seromucous exudate.

Fig. 4 Radiograph from normal goat skull

The lateral part of the mass causes destroyed ethmoid area; also, the mass was causing destruction and the coalescence of the bony cartilages of the nasal turbinates, but it never traversed the cribriform plate to the brain.

The tumor was unilateral in this case. In the histopathological examination, the tumor cells were arranged in acinar, tubular, papillary, and mixed patterns supported by negligible fibrovascular stroma. The tumor cells were generally uniform in pattern without atypia of cell. The tumor cells had a cuboidal to low columnar pattern with large round nucleus shapes. These types of cells were mainly arranged in a single layer, while mitotic figures were rare (Fig. 6a). Fewer macrophage and desquamated neoplastic epithelial cells non-ciliated were seen in the lumina of several neoplastic tubules. Also, mononuclear cell infiltrations in the stromal connective tissue around acinar of tumor cells were mainly observed (Fig. 6a, b). Lesions were not observed in any other organs with the exception of the foam in trachea and cerebral cortical necrosis in brain. Microscopically, well-differentiated nasal adenocarcinoma was diagnosed according to the characteristic microscopic features.

Discussion

Nasal adenocarcinomas are primarily tumors of the respiratory epithelium covering the respiratory portion (maxillaturbinates,

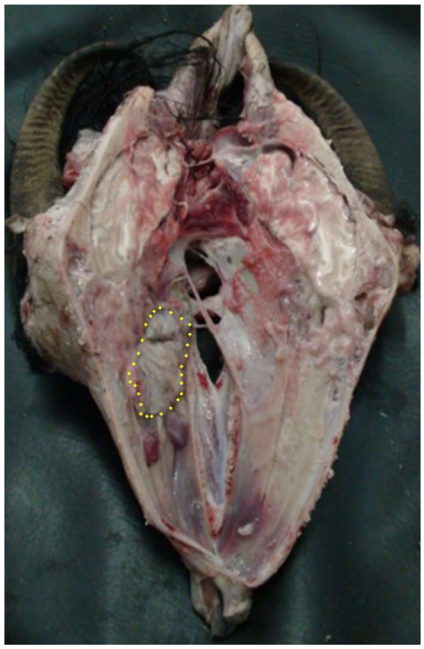

Fig. 5 A sagittal section of a goat head with a nasal tumor surface is irregular and cauliflower-like in the right ventral and dorsal concha in goat (dotted lines)

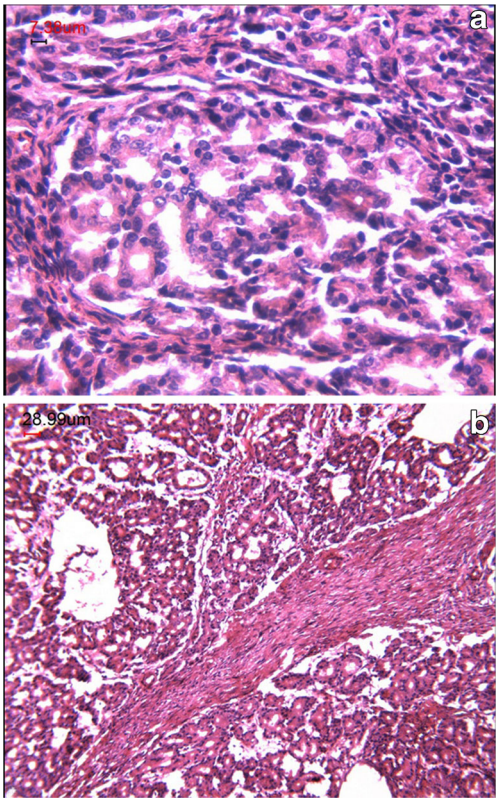

Fig. 6 **a** Low-grade nasal cell adenocarcinoma, goat. A group of neoplastic tubules and acini with cuboidal cells and large round nuclei with clumped chromatin and small nucleoli (H&E × 400). **b** Connective stroma is infiltrated with numerous lymphocyte and plasma cells (H&E × 100)

ethmoturbinates, nasoturbinates, and nasal septum) of the nose (Tuttle and Grier 1985). Enzootic intranasal tumors (ENTs) of sheep and goats are transmissible adenocarcinomas (Walsh et al. 2010). Similar to other contagious tumors of secretory epithelial cells such as sheep pulmonary adenomatosis and ENA of goats, they are accompanying with retroviruses (Cousens et al. 1996). Neoplastic changes of the secretory epithelial cells are a source of ENT in goats (De las Heras et al. 1991) rather than only Bowman's glands in the ethmoid turbinate of the upper respiratory tract (Wilson and Dungworth 2002; De las Heras et al. 2003) and can be caused by ENTV-2 infection in goat, which is a betaretrovirus (Cousens et al. 1996; Ozmen et al. 2010). It is highly homologous to both jaagsiekte retrovirus (JSRV) and ENTV but can be distinguished by unique genomic sequences (Kane et al. 2005). According to these reports, ENA is associated with the betaretrovirus; enzootic nasal tumor virus (ENTV) is divided into two distinct subspecies, one infecting sheep (ENTV-1) (Cousens et al. 1996) and another infecting goats (ENTV-2) (Ortin et al. 2003). Sporadic or many animals in a herd can be infected with ENTV. It is believed that the disease transmission occurred via respiratory droplets with nasal secretions that contain virus particles (Stowe et al. 2012). The most clinical signs in our study were seromucous exudates around the nares and respiratory distress, cachexia, and death. These findings are remarkably similar to those described in the veterinary literature (De las Heras et al. 1991; Ozmen et al. 2010; Aydogan et al. 2013; McKinnon et al. 1982). The neoplasia can be easily noticed by first endoscopic approaches (Weinreb 2010) and pathoanatomic investigation of sagittal section of the head like a white-gray mass with soft to firm consistency, which occludes the caudal part of one or both nasal cavities. To confirm the pathoanatomic diagnosis of ENA, histopathological examination must be performed (Sharp and De las Heras 2000; Svara et al. 2006). The value of gross examination of animal remains with nasal adenocarcinoma is well established (Stowe et al. 2012). The clinical demonstration and pathological findings in this tumor are the most reliable way to diagnose ENT as it bears significant similarities with nasal adenocarcinoma in sheep (Walsh et al. 2013). This suggests that such tumors in sheep (Walsh et al. 2013) and goats (Ortin et al. 2003) are caused by a retrovirus. Unfortunately, virological studies were not performed on tumor material from these goats. Several techniques including immunohistochemistry, electron microscopy, polymerase chain reaction (PCR), reverse transcriptase-PCR, and Western blotting have been developed for detection of the causative agent of ENA in neoplastic parenchyma and nasal exudates of affected animals (Svara et al. 2006; Walsh et al. 2013; Ortin et al. 2003). ENA cannot be detected by a serologic test because the virus stimulates no immune response (Scott 2011). Clinical manifestations are the definitive approaches for diagnosis of ENT (Chakraborty et al. 2014), and cytological or histopathological examination shows neoplastic cells (Stowe et al. 2012). Based on histopathological findings, ENA is classified as papillary, mucinous, tubular, and acinar patterns; however, in goats, carcinomas with papillary, tubular, or acinar patterns are also interpreted to be well-differentiated (low grade) carcinomas (Wilson and Dungworth 2002). Lack of obvious cellular atypia, usually very low mitotic index, and scant stromal or vascular invasion and lack of metastasis lead some authors to prefer the diagnosis of adenoma in goats. X-ray examination may also reveal increased soft tissue density of the nasal cavity or frontal sinuses, bony lysis, and destruction of the normal turbinate pattern (Svara et al. 2006), but initial assessment of a rudimentary nasal tumors is often more difficult to identify radiographic appearance because of the similarities in appearance at this stage to inflammatory reactions. There is no actual treatment for ENA, and majority of infected animals die within 90 days after the onset of the first clinical signs (Svara et al. 2006). Affected domestic species must be promptly culled once the diagnosis has been confirmed because they act as a source of virus for other animals in the flock, especially when closely confined. According to the histopathological findings, the tumor was classified as a low-grade adenocarcinoma but was associated with a poor prognosis.

Compliance with ethical standards

Conflict of interest The authors declare that they have no conflict of interest.

Ethical approval All of the ethical issues and also applicable international, national, and/or institutional guidelines were addressed throughout the study. In addition, this article does not contain any studies with animals performed by any of the authors and does not contain any studies with human participants or animals performed by any of the authors.

References

Aydogan A, Haligur M, Ozmen O (2013) The expression of caspase-3, caspase-7, caspase-9 and cytokeratin AE1/AE3 in goats with enzootic nasal adenocarcinoma: an immunohistochemical study. Vet Med 58(8):417–421

Chakraborty S, Kumar A, Tiwari R, Rahal A, Malik Y, Dhama K, Pal A, Prasad M (2014) Advances in diagnosis of respiratory diseases of small ruminants. Vet Med Int 2014:508304. https://doi.org/10.1155/2014/508304

Cousens C, Minguijon E, Garcia M, Ferrer LM, Dalziel RG, Palmarini M, de las Heras M, Sharp JM (1996) PCR-based detection and partial characterization of a retrovirus associated with contagious intranasal tumors of sheep and goats. J Virol 70(11):7580–7583

De las Heras M, Garcia de Jalon JA, Sharp JM (1991) Pathology of enzootic intranasal tumor in thirty-eight goats. J Vet Pathol 28(6):474–481. https://doi.org/10.1177/030098589102800603

De las Heras M, Garcia de Jalon JA, Minguijon E, Gray EW, Dewar P, Sharp JM (1995) Experimental transmission of enzootic intranasal tumors of goats. J Vet Pathol 32(1):19–23. https://doi.org/10.1177/030098589503200103

De las Heras M, Ortín A, Cousens C, Minguijon E, Sharp JM (2003) Enzootic nasal adenocarcinoma of sheep and goats. J Curr Top Microbiol Immunol 275:201–223

Dirks C, Duh FM, Rai SK, Lerman MI, Miller AD (2002) Mechanism of cell entry and transformation by enzootic nasal tumor virus. JVI 76(5):2141–2149. https://doi.org/10.1128/jvi.76.5.2141-2149.2002

Hindson JC, Winter AC (2002) Respiratory disease. In: Manual of sheep diseases, 2nd edn. Blackwell Science, Oxford, pp 196–209

Kane Y, Rosati S, Diop OM, Profiti I, Niang I, Kadja M et al (2005) Tissue targets and phylogenetic characteristic of the enzootic nasal tumour virus (ENTV) infecting sahelian sheep. Rev Med Vet 156:29–36

Lopez A (2012) Respiratory system, mediastinum, and pleurae. In: Zachary FJ, McGavin MD (eds) Pathologic basis of veterinary disease, 5th edn. Mosby-Elsevier Inc, St. Louis, pp 458–476

MacLachlan NJ, Dubovi EJ (2011) Retroviridae. In: Fenner's veterinary virology, 4th edn. Academic Press is an imprint of Elsevier, pp 257

McKinnon AO, Thorsen J, Hayes MA, Misener CR (1982) Enzootic nasal adenocarcinoma of sheep in Canada. Can Vet J 23(3):88–94

Ortin A, Cousens C, Minguijon E, Pascual Z, Villarreal MP, Sharp JM et al (2003) Characterization of enzootic nasal tumour virus of goats: complete sequence and tissue distribution. J Gen Virol 84(Pt 8):2245–2252. https://doi.org/10.1099/vir.0.19125-0

Ozmen O, Sahinduran S, Haligur M, Demir N (2010) Clinical, pathological, immunohistochemical and ultrastructural observations on enzootic nasal adenocarcinoma in five goats. Kafkas Univ Vet Fak Derg 16(4):633–639

Rajan A, Sulochana S, Sreekumaran T, Reddi MV, Nair MK (1980) Tumors of the ethmoid mucosa in goats (Capra Hhircus). Indian J Cancer 17(3):196–199

Scocco P, Mariotti F, Ceccarelli P, Fagioli O, Renzoni G, Vitellozzi G (2001) Origin of enzootic intranasal tumor in the goat (Capra hircus): a glycohistochemical approach. Vet Pathol 38(1):98–104. https://doi.org/10.1354/vp.38-1-98

Scott PR (2011) Treatment and control of respiratory disease in sheep. Vet Clin N Am Food Anim Pract 27(1):175–186. https://doi.org/10.1016/j.cvfa.2010.10.016

Sharp JM, De las Heras M (2000) Contagious respiratory tumours. In: Martin WB, Aitken ID (eds) Diseases of sheep, 3rd edn. Blackwell Science, Oxford, pp 184–186

Stowe DM, Anderson KL, Guy JS, Linder KE, Grindem CB (2012) A case of enzootic nasal adenocarcinoma in a ewe. J Vet Med 2012:1–4

Svara T, Gombac M, Vrecl M, Juntes P, Pogacnik M, Gombac M et al (2006) Enzootic nasal adenocarcinoma of sheep. J Slov Vet Res 43(2):71–75

Tuttle LE, Grier RL (1985) Nasal adenocarcinoma in the canine. Iowa State Univ Vet 47(1):41–45

Vitellozzi G, Mughetti L, Palmarini M, Mandara MT, Mechelli L, Sharp JM et al (1993) Enzootic intranasal tumour of goats in Italy. Zentralbl Veterinar Med B 40:459–468

Walsh SR, Linnerth-Petrik NM, Laporte AN, Menzies PI, Foster RA, Wootton SK (2010) Full-length genome sequence analysis of enzootic nasal tumor virus reveals an unusually high degree of genetic stability. J Virus Res 151(1):74–87. https://doi.org/10.1016/j.virusres.2010.04.002

Walsh SR, Linnerth-Petrik NM, Yu DL, Foster RA, Menzies PI, Diaz-Méndez A et al (2013) Experimental transmission of enzootic nasal adenocarcinoma in sheep. Vet Res:44–66

Weinreb I (2010) Low grade glandular lesions of the sinonasal tract: a focused review. Head Neck Pathol 4(1):77–83. https://doi.org/10.1007/s12105-009-0159-5

Wilson DW, Dungworth DL (2002) Tumors of the respiratory tract. In: Meuten DJ (ed) Tumors in the domestic animals, 4th edn. Iowa State Press, Iowa, pp 374–375

Yi G, Kaiyu W, Qigui Y, Zhongqiong Y, Yingdong Y, Defang C, Jinlu H (2010) Descriptive study of enzootic nasal adenocarcinoma in goats in southwestern China. Transbound Emerg Dis 57(3):197–200. https://doi.org/10.1111/j.1865-1682.2010.01097.x

Yu DL, Linnerth-Petrik NM, Halbert CL, Walsh SR, Miller AD, Wootton SK (2011) Jaagsiekte sheep retrovirus and enzootic nasal tumor virus promoters drive gene expression in all airway epithelial cells of mice but only induce tumors in the alveolar region of the lungs. J Virol 85(15):7535–7545. https://doi.org/10.1128/JVI.00400-11