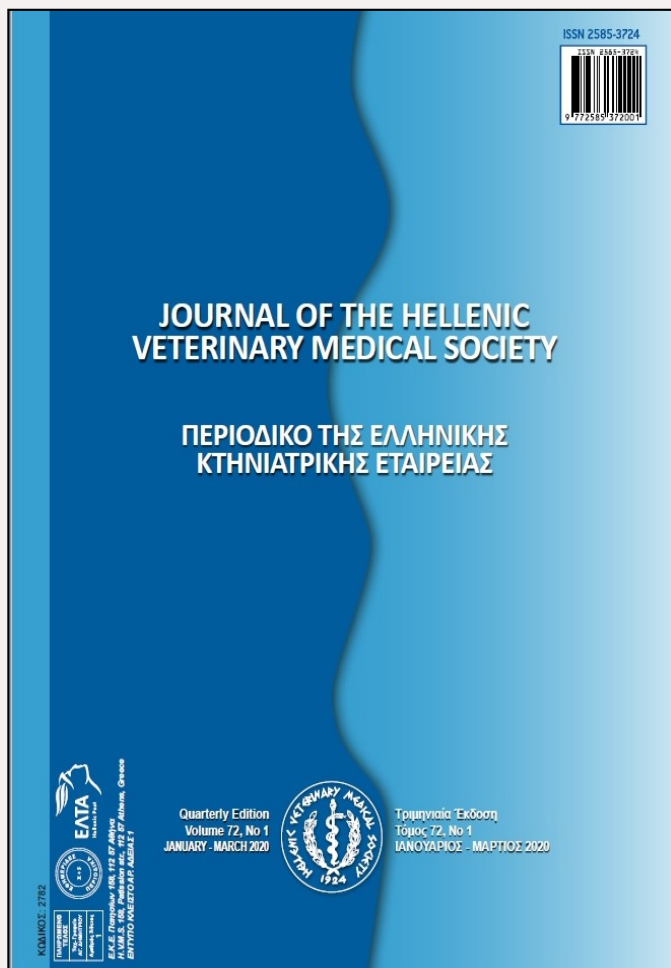

# Journal of the Hellenic Veterinary Medical Society

Vol. 72, 2021



## A clinical survey on the electrocardiogram after intravenous granisetron hydrochloride administration in clinically normal dogs

GHAEMI H	Faculty of Veterinary Medicine, Ferdowsi University of Mashhad, Mashhad, Iran
SALARI SEDIGH H	Department of Clinical Sciences, Faculty of Veterinary Medicine, Ferdowsi University of Mashhad, Mashhad, Iran
SELK GHAFFARI M	Department of Veterinary Clinical Sciences, Karaj Branch, Islamic Azad University, Karaj, Iran

<https://doi.org/10.12681/jhvms.26754>

Copyright © 2021 H GHAEMI, H SALARI SEDIGH, M SELK GHAFFARI



### To cite this article:

GHAEMI, H., SALARI SEDIGH, H., & SELK GHAFFARI, M. (2021). A clinical survey on the electrocardiogram after intravenous granisetron hydrochloride administration in clinically normal dogs. *Journal of the Hellenic Veterinary Medical Society*, 72(1), 2695-2702. doi:<https://doi.org/10.12681/jhvms.26754>

## A clinical survey on the electrocardiogram after intravenous granisetron hydrochloride administration in clinically normal dogs

H. Ghaemi<sup>1</sup>, H. Salari Sedigh<sup>2\*</sup>, M. Selk Ghaffari<sup>3</sup>

<sup>1</sup> Faculty of Veterinary Medicine, Ferdowsi University of Mashhad, Mashhad, Iran

<sup>2</sup> Department of Clinical Sciences, Faculty of Veterinary Medicine, Ferdowsi University of Mashhad, Mashhad, Iran

<sup>3</sup> Department of Veterinary Clinical Sciences, Karaj Branch, Islamic Azad University, Karaj, Iran

**ABSTRACT:** Cardiac side effect of 5-hydroxytryptamine-3 receptor antagonists has been a concern for clinicians. There is a substantial need for greater clarity about the safety of granisetron hydrochloride, an antiemetic agent of this class used in oncological and parvoviral gastroenteritis with acute vomiting in dogs. This study aimed to assess the electrocardiographic effects of a single dose of intravenous granisetron. We randomly assigned 16 adult crossbreed female healthy dogs into two groups of intervention and control and injected them intravenously with granisetron and normal saline, respectively, at a dose of 0.5 ml/kg over one minute. Standard electrocardiography (ECG) was recorded at the baseline, as well as 5, 15, 30, 60, 120, 360, and 720 minutes after the intervention. Heart rate and ECG parameters (PR intervals, QRS duration, ST-segment, T-wave amplitudes, QT, JT, QTc and JTc intervals) were evaluated in lead II. No significant difference was observed between the intervention and the control groups in any of the measured variables at any of the time-points. Mean values of measured parameters showed no significant difference compared with baseline values in the control group, while the granisetron group saw statistically significant but clinically asymptomatic changes in heart rate, PR, QRS, QT, JT, and QTc at different time-points, compared to the baseline values ( $P < 0.05$ ). In conclusion, Granisetron administration was not associated with clinically significant adverse effects on ECG variables or heart rate. Thus, it can be regarded as a relatively safe drug.

**Keywords:** Granisetron hydrochloride, QTc, JTc, Electrocardiogram, Dog.

*Corresponding Author:*  
Hamideh Salari Sedigh, Department of Clinical Sciences, Faculty of Veterinary Medicine, Ferdowsi University of Mashhad, Mashhad, Iran  
E-mail address: hssedigh@um.ac.ir

*Date of initial submission: 13-03-2020*  
*Date of revised submission: 09-06-2020*  
*Date of acceptance: 27-07-2020*

## INTRODUCTION

Nausea and vomiting are among the commonly encountered side effects in patients undergoing chemotherapy, occurring in most cytostatic chemotherapeutic regimens among cancer patients (Harris 2010; Janelsins et al. 2013; Schnell 2003; Yamakuni et al. 2000). Moreover, severe gastroenteritis especially in puppies with parvoviral infection can be a major cause of nausea and vomiting in animals (Goddard and Leisewitz 2010; Nandi and Kumar 2010; Woods et al. 1980). These emesis occurring within 24 hours, is now known to be mediated via 5-hydroxytryptamin<sub>3</sub> (5-HT<sub>3</sub>) receptors and thus can be controlled with the specific 5-HT<sub>3</sub> receptor antagonists (Grunberg 1993; Hsu 2010). Granisetron, ondansetron, and tropisetron, having been considered the most powerful antiemetics so far, have been proven at least equally efficacious as conventional treatments (Chevallier 1993; Gomez-de-Segura et al. 1998; Gregory and Ettinger 1998; Hsu 2010; Janelsins et al. 2013; Schnell 2003).

5-HT<sub>3</sub> receptor antagonists, however, have been reportedly associated with an increased risk of abnormalities in cardiac repolarization. For instance, some studies have reported adverse electrocardiographic effects from granisetron and raised concerns over the possibility of this drug causing arrhythmia (Buyukavci et al. 2005; Pinarli et al. 2006). Previous studies have stated that efficacy of 5-HT<sub>3</sub> receptor antagonists when used intravenously outweighs their risk and small, transient electrocardiographic abnormalities that might appear are clinically insignificant (Cakir et al. 2012; Coop 2003; Ghaffari et al. 2010; Keefe 2002; Navari and Koeller 2003).

However, available evidence is not sufficient to warrant their safety, especially in patients with preexisting cardiovascular disorders or those receiving cardiotoxic drugs e.g. chemotherapeutic regimens. Potential cardiovascular adverse effects of 5-HT<sub>3</sub> receptor antagonists have attracted growing research interest and studies have investigated the safety of some of these agents. Nevertheless, an interventional animal study to evaluate the electrocardiographic effects of granisetron and its safety compared with placebo is lacking (Dennis et al. 2007; Ghaffari et al. 2010; Tricco et al. 2016). Therefore, the present study was aimed to assess the electrocardiographic effects of single-dose intravenous administration of granisetron on healthy dogs, as animal models.

## MATERIALS AND METHODS

### Study Design

The "The first evaluation of the electrocardio-

graphic effects of iv granisetron (As hydrochloride) 3 mg (Caspian Tamin, Iran) in healthy dogs» was an experimental, randomized, placebo-controlled study. The study was approved by the Iran Society for Prevention of Cruelty to Animals in accordance with Iranian ethical codes for studies on laboratory animals. The contract between the sponsor (Ferdowsi University of Mashhad) and the guide investigator provided that the latter would have full access to all results and the right to independently publish the study regardless of the outcome.

### Animals

In this experimental study, 16 adult crossbreed female dogs with a mean weight of 23.32±0.78 kg were included. The study was performed completely according to the principles of the World Medical Association (WMA) statement on animal use in biomedical research. For a period of two weeks before the intervention, all included dogs were housed individually in cages in an animal room with standard and monitored conditions for environmental adaptation. Water and commercial dry dog foods were given to the dogs ad libitum during the study. The dogs were vaccinated and antiparasitic agents were given to them.

All dogs underwent thorough physical examination, blood and fecal analysis before the study and standard electrocardiography at the baseline and their condition were confirmed as healthy based on the results.

Exclusion criteria: Dogs were excluded from the study if they had cardiovascular disease and clinically relevant systemic disease.

We removed the dogs from their home cages and took them to a quiet room two hours before the intervention so that they can acclimatize to the environment.

The dogs were randomly assigned to two different groups of intervention (N=8) and control (N=8). The intervention group received intravenous granisetron, injected slowly at a dose of 0.5 ml/kg over one minute, while the control group received intravenous normal saline at the exact same dose and condition.

A 6-lead standard electrocardiogram (ECG) comprising leads I, II, III, aVR, aVL, and aVF was performed using a single channel digital electrocardiograph (ECG 110, Kenzo®, Suzuken, Japan) and recorded at 50 mm/s and 10 mm/mv for all dogs, while they were in right lateral recumbency position on a table. All ECGs were performed by one single

expert operator observing the standard conditions.

One-minute ECGs of lead II were recorded in all dogs at baseline and 5, 15, 30, 60, 120, 360, and 720 minutes after the intervention. In all ECGs taken, heart rate, PR interval, QRS duration, ST segment, T-wave amplitude, QT interval, and JT interval were recorded in checklists for each dog. The JT interval was calculated by subtracting QRS duration from the QT interval, measured from the endpoint of QRS complex (known as j-point) to the endpoint of T wave, marking the point that T wave returns to the isoelectric line. Moreover, we calculated the rate-corrected QT and JT intervals, being known as QTc and JTc, respectively, using the formulas below.

$$JTc = \frac{JT}{\sqrt[3]{RR}} \quad QTc = \frac{QT}{\sqrt[3]{RR}}$$

### Statistical Methods

Statistical analysis was performed using the statistical package for social sciences (SPSS; version 12.0 for Windows, IBM Statistics, Chicago, IL, USA). One-sample Kolmogorov-Smirnov test was used to assess the normal distribution of data. Independent samples t-test was used to compare the measured parameters in each time-point between the two groups. Paired samples t-test was used to compare data with the baseline values in each group.  $P < 0.05$  was consid-

ered as statistically significant.

### RESULTS

Overall, 16 dogs in two groups of intervention (N=8) and control (N=8) were studied. The electrocardiographic parameters of dogs in both groups are shown in Table-1. As the table implies, in the control group, none of the measured parameters changed significantly at any of the time-points, compared with their baseline values. However, in the intervention group, several parameters were changed significantly at different time-points, compared with baseline values.

Mean heart rate of the intervention group was significantly different from their baseline heart rate 30, 60, and 120 minutes after the intervention ( $P=0.033$ ,  $P=0.033$ , and  $P=0.015$ , respectively). In the intervention group, mean QRS duration 5 minutes after the intervention and mean QTc interval 15 minutes after the intervention was significantly different from the corresponding baseline values ( $P=0.011$  and  $P=0.037$ ). Moreover, mean values of PR, QT, and JT intervals 5, 15, 30, 60, 120, and 360 minutes after the intervention was significantly different from the baseline value in the intervention group ( $P < 0.05$ ). Nevertheless, mean values of ST segment, JTc interval, and T wave amplitude had no significant change over the course of study in the intervention group.

**Table 1.** Mean values of electrocardiographic parameters in intervention and control groups at different time-points

Parameter	baseline	5 min	15 min	30 min	60 min	120 min	360 min	720 min	
HR	I	90.00±5.34	82.50±4.53	85.00±6.26	<b>80.00±5.34</b>	<b>80.00±5.34</b>	<b>78.75±6.10</b>	82.50±5.90	92.50±7.50
	C	90.00±8.16	85.00±7.18	80.00±8.56	86.66±7.60	78.33±4.77	81.66±5.42	93.33±9.54	88.33±7.03
PR	I	0.106±0.007	<b>0.117±0.010</b>	<b>0.117±0.009</b>	<b>0.120±0.008</b>	<b>0.120±0.009</b>	<b>0.117±0.009</b>	<b>0.119±0.008</b>	0.110±0.007
	C	0.101±0.005	0.087±0.006	0.095±0.005	0.099±0.004	0.099±0.005	0.100±0.007	0.0091±0.008	0.100±0.005
QRS	I	0.093±0.003	<b>0.098±0.003</b>	0.099±0.003	0.095±0.003	0.094±0.003	0.094±0.004	0.094±0.003	0.090±0.004
	C	0.954±0.005	0.096±0.005	0.097±0.006	0.098±0.005	0.096±0.003	0.096±0.005	0.099±0.005	0.100±0.004
ST	I	0.064±0.019	0.083±0.007	0.075±0.022	0.061±0.021	0.065±0.021	0.087±0.005	0.077±0.009	0.085±0.006
	C	0.052±0.026	0.033±0.031	0.034±0.031	0.060±0.026	0.031±0.035	0.055±0.027	0.062±0.027	0.060±0.026
QT	I	0.273±0.011	<b>0.290±0.011</b>	<b>0.295±0.009</b>	<b>0.288±0.009</b>	<b>0.293±0.014</b>	<b>0.292±0.013</b>	<b>0.292±0.012</b>	0.277±0.009
	C	0.272±0.006	0.279±0.005	0.276±0.007	0.275±0.007	0.276±0.006	0.280±0.006	0.274±0.009	0.273±0.007
JT	I	0.180±0.009	<b>0.192±0.009</b>	<b>0.196±0.008</b>	<b>0.193±0.007</b>	<b>0.198±0.011</b>	<b>0.197±0.010</b>	<b>0.198±0.009</b>	0.187±0.007
	C	0.176±0.009	0.182±0.007	0.178±0.010	0.177±0.009	0.179±0.008	0.184±0.009	0.174±0.009	0.173±0.008
QTc	I	0.309±0.008	0.318±0.007	<b>0.322±0.006</b>	0.312±0.008	0.311±0.010	0.314±0.012	0.315±0.009	0.311±0.008
	C	0.306±0.007	0.314±0.009	0.301±0.007	0.303±0.008	0.308±0.008	0.311±0.004	0.313±0.006	0.315±0.007
JTc	I	0.204±0.007	0.210±0.007	0.213±0.006	0.209±0.005	0.288±0.025	0.211±0.009	0.213±0.007	0.209±0.007
	C	0.198±0.010	0.205±0.008	0.199±0.011	0.195±0.009	0.199±0.007	0.204±0.008	0.199±0.008	0.198±0.005
TWA	I	0.100±0.106	0.007±0.111	0.001±0.111	-0.003±0.104	0.024±0.127	0.044±0.011	0.065±0.119	0.050±0.083
	C	0.068±0.171	0.219±0.173	0.053±0.207	0.089±0.118	-0.034±0.173	0.028±0.175	0.044±0.151	-0.004±0.165

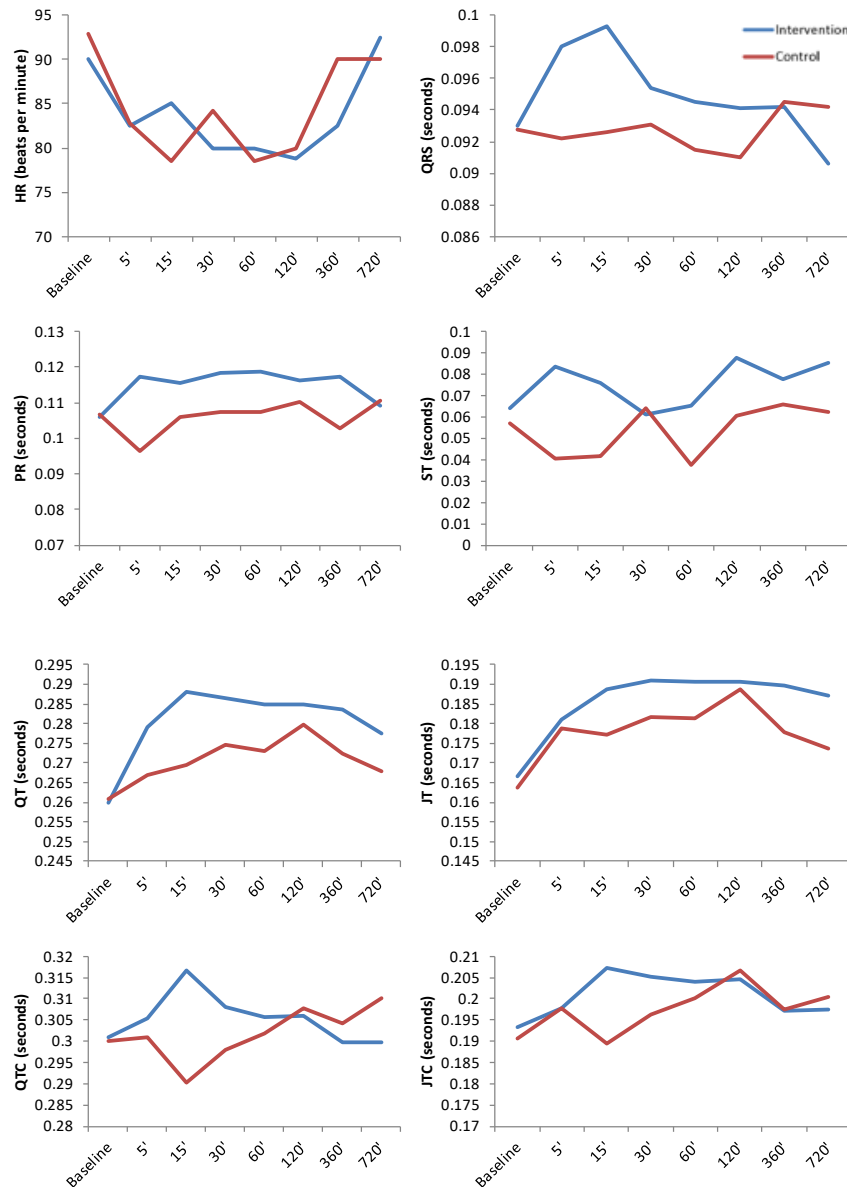
HR: heart rate; TWA: T wave amplitude; I: intervention; C: control

\*Values shown in bold were significantly different from the baseline value in that group, according to paired samples t-test ( $P < 0.05$ )

Figure-1 shows the alterations in mean values of heart rate, PR interval, QRS duration, ST segment, QT interval, JT interval, QTc, and JTc in each of the intervention and control groups and compares the trend of changes between the dogs in these two groups. Figure-2 compares the changes in mean T wave amplitude between the intervention and the control groups. The intervention and the control groups showed no

significant differences in any of the measured parameters at any of the time-points.

Regarding the side effects of the treatment, a second-degree ventricular block was seen in one dog (12.5%) in the intervention group, which is presented in Figure-3. In contrast, none of the dogs in the control group showed any notable change in cardiac rhythm.



**Figure 1.** Comparison of the changes in mean values of some measured parameters over the first twelve hours after the intervention between the intervention and the control groups

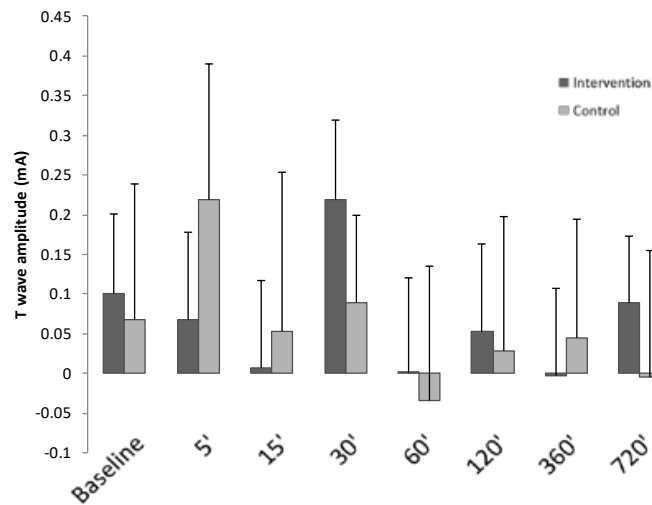


Figure.2. Comparison of the changes in mean T wave amplitude between the intervention and the control groups

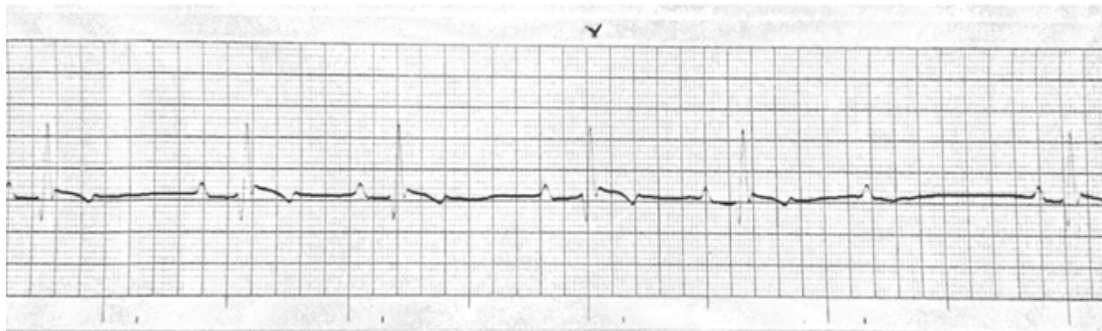


Figure.3. Second-degree ventricular block in one dog in the intervention group

## DISCUSSION

Granisetron has been emerged as a potent anti-emetic agent with manifold indications in different conditions. However, there is not enough evidence to draw a firm conclusion on the safety of this drug. The present work is one of the few studies investigating the electrocardiographic safety of this drug and probably the first study to investigate this issue in animal models. In this study we only included female dogs because female dogs possess larger potassium channels in the epicardium and endocardium, which in turn provides a greater repolarization gradient and longer QT intervals compared with male dogs (Xiao et al. 2006).

We found no significant difference regarding any of the measured variables at any of the time-points between the intervention and control group. This find-

ing is in line with several other studies comparing the cardiac effects of granisetron with placebo among healthy adults (Boike et al. 1997; Mason et al. 2013; Mason et al. 2012).

Mason and colleagues in a double-blinded randomized placebo-controlled crossover trial on healthy subjects compared subcutaneous and intravenous granisetron with placebo over a 49-hour period in terms of ECG changes. They found no clinically significant difference in any of the electrocardiographic parameters between granisetron and control groups (Mason et al. 2014).

Similarly, Mason et al. in another randomized controlled crossover trial, evaluated 12-lead ECGs in healthy subjects receiving subcutaneous APF530 (sustained-release granisetron) and intravenous gran-

isetron with placebo and found no clinically significant difference in electrocardiographic parameters of the subjects (Mason et al. 2013).

We also found that in the control group, none of the measured parameters changed significantly from the baseline at any of the time-points. However, in the intervention group, statistically significant changes in measured parameters were seen compared with baseline at some points in the study, including reduced heart rate as well as an increase in QRS duration and PR, QT, QTc, and JT intervals. However, the changes were not clinically significant, with the exception of a second-degree ventricular block in the group receiving granisetron.

In fact, granisetron can potentially affect PR, QT, and JT intervals and QRS duration by blocking both the sodium and rapid potassium channels. Therefore, we can attribute the changes in ECG parameters in our study to blockade of sodium and potassium channels in myocytes, both of which can lead to ventricular dysrhythmias (Jantunen et al. 1996; Kuryshv et al. 2000).

As our findings indicate increased QT interval in some time-points among the intervention groups, given that QT interval comprises QT and QRS, we can state that both depolarization and repolarization of ventricles are affected by granisetron.

Although no previous study has investigated the electrocardiographic side effects of granisetron in animal models, our results were comparable to human studies on this subject, which reported statistically significant changes in parameters of ECG including PR interval, QT interval, QRS duration, and QT interval (Boike et al. 1997; Hunt et al. 1995; Schnell 2003; Tricco et al. 2016).

Moreover, some studies have reported the electrocardiographic effects of ondansetron, another 5-HT<sub>3</sub> receptor antagonist, in animal models. Williams et al. reported that ondansetron can increase the QTc interval in a dose-dependent manner in anesthetized dogs. They also suggested that this effect could be attributed to the effects of this drug on potassium channels (Williams et al. 1991). In another animal study by Ghaffari and colleagues, standard doses of ondansetron were introduced to eight crossbreed dogs and the results indicated a significant increase in QT interval along with significantly decreased heart rate (Ghaffari et al. 2010).

In the present study, we observed a decrease in heart rate of dogs in the granisetron group, started 30 minutes after the intervention and continuing for 2 hours, though being insignificant. We hypothesize that granisetron can decrease the heart rate through blocking serotonin receptors on the afferent vagus nerve in the gastrointestinal tract and the feedback mechanism (Buyukavci et al. 2005; Spartinou et al. 2017).

Our study had some limitations. One of the limitations was our small sample size, which increases the chance of biases. Another limitation was using a single dose and only one mode of delivering the drug. Evaluating the effects of divided doses during the day and other modes of delivery such as subcutaneous granisetron could have been of benefit.

Since over 85% of cardiovascular toxicities have been predicted by animal studies on dogs, it can be posited that there are physiologic proximities between canine and human species (Gralinski 2003). Therefore, our findings can be of cardinal importance in directing further human research regarding the cardiotoxic effects of granisetron by providing several useful insights into the safety of this drug when used in healthy dogs.

## CONCLUSIONS

Our findings indicate that despite granisetron at 0.5 mg/kg b.w. intravenously can lead to some electrocardiographic changes, which are mostly mild, trivial, and clinically insignificant. Therefore, it can be said that granisetron has transient and subclinical effects on the electrocardiographic parameters. Clinical electrocardiographic manifestations of granisetron can thus be possibly seen in patients with history of arrhythmia, conductive heart disorders, electrolyte disturbances (especially hypokalemia, which can be caused by viral gastroenteritis), those receiving cardiotoxic chemotherapy regimens, or patients with physiologic long QT intervals.

## ACKNOWLEDGMENTS

The authors thank the Vice Chancellor for Research of Ferdowsi University of Mashhad for financial supports (Protocol Code: 3/ 29801). This article is the outcome of DVM student thesis. In addition, the authors gratefully appreciate the cooperation of Dr. Masoud Rajabioun for his expert technical assistance.

## REFERENCES

- Boike SC, ILson B, Zariffa N, Jorkasky DK (1997) Cardiovascular effects of iv granisetron at two administration rates and of ondansetron in healthy adults *American journal of health-system pharmacy* 54:1172-1176
- Buyukavci M, Olgun H, Ceviz N (2005) The effects of ondansetron and granisetron on electrocardiography in children receiving chemotherapy for acute leukemia *American journal of clinical oncology* 28:201-204
- Cakir F, Yapar O, Canpolat C, Akalin F, Berrak S (2012) Cardiac effects of granisetron in a prospective crossover randomized dose comparison trial *Supportive Care in Cancer* 20:2451-2457
- Chevallier B (1993) on behalf of the Granisetron Study Group: The control of acute cisplatin-induced emesis. A comparative study of granisetron and a combination regimen of high-dose metoclopramide and dexamethasone *Br J Cancer* 68:176-180
- Coop AJ (2003) Comment: electrocardiographic and cardiovascular effects of the 5-hydroxytryptamine-3 receptor antagonists *Annals of Pharmacotherapy* 37:1918-1918
- Dennis S, Wotton P, Boswood A, Flaherty D (2007) Comparison of the effects of thiopentone and propofol on the electrocardiogram of dogs *The Veterinary Record* 160:681-686
- Ghaffari MS, Moghaddassi AP, Khorami N (2010) The acute effects of ondansetron on the electrocardiogram in clinically normal dogs *Comparative clinical pathology* 19:499-502
- Goddard A, Leisewitz AL (2010) Canine parvovirus *Veterinary Clinics: Small Animal Practice* 40:1041-1053
- Gomez-de-Segura IA, Grande AG, De Miguel E (1998) Antiemetic effects of Lerisetron in radiation-induced emesis in the dog *Acta Oncologica* 37:759-763
- Gralinski MR (2003) The dog's role in the preclinical assessment of QT interval prolongation *Toxicologic pathology* 31:11-16
- Gregory RE, Ettinger DS (1998) 5-HT<sub>3</sub> receptor antagonists for the prevention of chemotherapy-induced nausea and vomiting *Drugs* 55:173-189
- Grunberg SM (1993) Potential for combination therapy with the new anti-serotonergic agents *European Journal of Cancer* 29:S39-S41
- Harris DG (2010) Nausea and vomiting in advanced cancer *British medical bulletin* 96:175-185
- Hsu ES (2010) A review of granisetron, 5-hydroxytryptamine<sub>3</sub> receptor antagonists, and other antiemetics *American journal of therapeutics* 17:476-486
- Hunt TL, Cramer M, Shah A, Stewart W, Benedict CR, Hahne WF (1995) A Double-Blind, Placebo-Controlled, Dose-Ranging Safety Evaluation of Single-Dose Intravenous Dolasetron in Healthy Male Volunteers *The Journal of Clinical Pharmacology* 35:705-712
- Janelins MC, Tejani MA, Kamen C, Peoples AR, Mustian KM, Morrow GR (2013) Current pharmacotherapy for chemotherapy-induced nausea and vomiting in cancer patients *Expert opinion on pharmacotherapy* 14:757-766
- Jantunen IT, Kataja VV, Muhonen TT, Parviainen T (1996) Effects of granisetron with doxorubicin or epirubicin on ECG intervals *Cancer chemotherapy and pharmacology* 37:502-504
- Keefe DL (2002) The cardiotoxic potential of the 5-HT<sub>3</sub> receptor antagonist antiemetics: is there cause for concern? *The Oncologist* 7:65-72
- Kuryshv YA, Brown AM, Wang L, Benedict CR, Rampe D (2000) Interactions of the 5-hydroxytryptamine 3 antagonist class of antiemetic drugs with human cardiac ion channels *Journal of Pharmacology and Experimental Therapeutics* 295:614-620
- Mason J, Moon TE, O'Boyle E, Dietz AJ (2013) Comparison of the effects of subcutaneous APF530, intravenous granisetron, moxifloxacin, and placebo on the QT interval in humans. *American Society of Clinical Oncology*,
- Mason JW, Moon TE, O'Boyle E, Dietz A (2014) A randomized, placebo-controlled, four-period crossover, definitive QT study of the effects of APF530 exposure, high-dose intravenous granisetron, and moxifloxacin on QTc prolongation *Cancer management and research* 6:181
- Mason JW, Selness DS, Moon TE, O'Mahony B, Donachie P, Howell J (2012) Pharmacokinetics and repolarization effects of intravenous and transdermal granisetron *Clinical Cancer Research* 18:2913-2921
- Nandi S, Kumar M (2010) Canine parvovirus: current perspective *Indian Journal of Virology* 21:31-44
- Navari RM, Koeller JM (2003) Electrocardiographic and cardiovascular effects of the 5-hydroxytryptamine<sub>3</sub> receptor antagonists *Annals of Pharmacotherapy* 37:1276-1286
- Pınarlı F, Elli M, Dağdemir A, Baysal K, Acar S (2006) Electrocardiographic findings after 5-HT<sub>3</sub> receptor antagonists and chemotherapy in children with cancer *Pediatric blood & cancer* 47:567-571
- Schnell FM (2003) Chemotherapy-induced nausea and vomiting: the importance of acute antiemetic control *The oncologist* 8:187-198
- Spartinou A, Nyktari V, Papaioannou A (2017) Granisetron: a review of pharmacokinetics and clinical experience in chemotherapy induced-nausea and vomiting *Expert opinion on drug metabolism & toxicology* 13:1289-1297
- Tricco AC et al. (2016) Comparative safety and effectiveness of serotonin receptor antagonists in patients undergoing chemotherapy: a



- systematic review and network meta-analysis *BMC Medicine* 14:216  
doi:10.1186/s12916-016-0761-9
- Williams PD, Cohen ML, Turk JA (1991) Electrocardiographic effects of zatosetron and ondansetron, two 5HT<sub>3</sub> receptor antagonists, in anesthetized dogs *Drug development research* 24:277-284
- Woods C, Pollock R, Carmichael L (1980) Canine parvoviral enteritis *Journal of the American Animal Hospital Association* 16:171-179
- Xiao L, Zhang L, Han W, Wang Z, Nattel S (2006) Sex-based transmural differences in cardiac repolarization and ionic-current properties in canine left ventricles *American Journal of Physiology-Heart and Circulatory Physiology* 291:H570-H580
- Yamakuni H et al. (2000) Probable Involvement of the 5-Hydroxytryptamine<sub>4</sub>Receptor in Methotrexate-Induced Delayed Emesis in Dogs *Journal of Pharmacology and Experimental Therapeutics* 292:1002-1007