



# Clinical and mycological features of dermatophytosis in domestic cats at Ferdowsi University of Mashhad Veterinary Teaching Hospital

Zohreh Ghiasi Tarzi<sup>a</sup>, Samaneh Eidi<sup>b</sup>, Javad Khoshnegah<sup>c</sup>

<sup>a</sup> Graduated from Faculty of Veterinary Medicine, Ferdowsi University of Mashhad, Mashhad, Iran.

<sup>b</sup> Department of Pathobiology, Faculty of Veterinary Medicine, Ferdowsi University of Mashhad, Mashhad, Iran.

<sup>c</sup> Department of Clinical Sciences, Faculty of Veterinary Medicine, Ferdowsi University of Mashhad, Mashhad, Iran.

## ABSTRACT

The aim of this study was to investigate the clinical manifestations and mycological features of feline dermatophytosis in a population of cats with suspected lesions of dermatophytosis at Ferdowsi University of Mashhad Veterinary Teaching Hospital (northeast of Iran). Skin, hair, and nail samples from 122 clinically suspected cases of feline dermatophytosis were screened by direct microscopic examination. Of the 122 samples examined, 91 (74.59 %) were positive for fungal elements by direct microscopic examination, and 66 (54 %) were culture-positive for *Microsporum canis*. *M. canis* was the only dermatophyte species isolated from the cats. In the studied population, young cats (< 7 months) showed a statistically higher rate of *M. canis* infection than older animals ( $p < 0.001$ ). The occurrence of dermatophytosis did not correlate with gender or the type of cats' hair. The isolation rate of dermatophytes was relatively high in winter. However, the association between season and the dermatophyte inflation rate was not significant. The diagnostic value of microscopic examination proved to be high compared to fungal cultures as 64 of 66 samples that had positive *M. canis* culture were positive at microscopic examination. The agreement between culture and microscopic examination was moderate ( $k = 0.49$ ). The information acquired in this study provides helpful insights into dermatophytoses in northern Iran highlighting the most important clinical and mycological features of skin mycoses in pet cats.

## Keywords

Dermatophyte, Dermatophytosis, *Microsporum*, *Microsporum canis*, Cat, Iran

Number of Figures: 1  
Number of Tables: 2  
Number of References: 32  
Number of Pages: 7

## Abbreviations

*M. canis*: *Microsporum canis*  
KOH: Potassium hydroxide  
DMSO: Dimethyl sulfoxide  
SCC: Sabouraud agar with cycloheximide and chloramphenicol  
 $\chi^2$ : Chi-square

<https://IJVST.um.ac.ir>

Corresponding author: Javad Khoshnegah  
Email: [khoshnegah@um.ac.ir](mailto:khoshnegah@um.ac.ir)  
Tel: +98 (511) 3880-5612

**D**ermatophytosis is the most common fungal infection of cats worldwide and one of the most important infectious skin diseases in this species [1]. The prevalence of dermatophyte isolation, especially that of *M. canis*, varied among the populations depending on the geographic region, whether or not the cat was a stray or pet cat, and the presence or absence of skin disease at the time of sampling [1]. In Mashhad (northeast of Iran), a very low prevalence of dermatophytosis has been reported in dogs (1/218 dogs with dermatologic manifestations) and a very high prevalence in cattle (490/684 cattle with dermatologic manifestations) based on culture results [2, 3]. According to a study on the fungal agents of animals, cats (36.3%) were the most prevalent infected animals, followed by camels (13.4%), dogs (12.8%), horses (12.5%), cows (12.3%) [4]. In Turkey (located in the west of Iran), the isolation rates of dermatophyte species from dogs and cats were 18.7% and 20.1%, respectively [5]. In other countries, a wide range of prevalence of feline dermatophytosis from 4% to 91% has been reported [6-13].

Feline dermatophytosis is most often characterized principally by one or more irregular or annular areas of alopecia with or without scales [14, 15]. However, there are some other clinical presentations of feline dermatophytosis, such as inflammatory areas of folliculitis characterized by alopecia, erythema, scale, crust, follicular papules, military dermatitis, chin folliculitis, dermatitis of the dorsal tail and onychomycosis [16, 17]. In general, the nature of the dermatophyte cannot be determined from the clinical presentation [15, 18].

Various risk factors have been described for feline dermatophytosis. Some authors suggest that the highest incidence of dermatophytosis might be found in kittens, immunocompromised animals, and long-haired animals (e.g., Persians) [5-7, 15, 19]. The current study was designed to assess the clinical manifestations and mycological features of feline dermatophytosis in a population of Iranian domestic cats with suspected lesions of dermatophytosis presented at a veterinary teaching hospital.

**Location of the study:** Mashhad is a large city located in the northeast of Iran close to the borders of Afghanistan and Turkmenistan. It is located in the valley of the Kashaf River between the two mountain ranges of Binalood and Hezar-Masjed. The city's climate is semi-arid with cold winters and moderate summers. It has a resident population of approximately 3,400,000 [20].

**Ethical Considerations:** This research proposal has received ethical approval from Ferdowsi University of Mashhad Research Office. In addition, the National Research Council's guide for the care and use of animals was followed.

**Study population and sample size:** During the study period (September 2017 to November 2018), animals with skin lesions, such as alopecia, peripheral scaling, erythema, crust, popular lesions, military dermatitis, and onychomycosis, classified as suspected cases of dermatophytosis, were sampled [15]. Convenience sampling was used in the selection of animals. Overall, in the present study, 122 cats with suspected lesions of dermatophytosis were examined.

**Sampling and examination procedures:** All cats with suspected skin lesions of dermatophytosis were closely examined, including observation and palpation of the skin for any kind of primary and/or secondary skin lesions. The anatomic location(s) of the skin lesions were recorded.

Hair samples were collected based on the clinical signs using Wood's lamp examination. The method of hair sampling was chosen according to the clinical signs and was either by the toothbrush technique when lesions were generalized or by hair pluck of the margins of localized lesions [21, 22]. The samples were sent to the Mycology Laboratory of the Faculty of Veterinary Medicine, Ferdowsi University of Mashhad, Iran. None of the sampled animals was treated with an antifungal agent.

**Data collection:** Age, gender, and hair type of sampled animals were recorded. Cats were classified into four groups based on their age [23] as younger than 7 months ( $\leq 7$  months), 7 months to 2 years (7 months-2 years), 2-6 years ( $\geq 2-6$  years), and older than 6 years ( $\geq 6$  years). To evaluate seasonal effects, the samples were categorized according to the sampling periods into spring, summer, autumn, and winter groups.

**Direct microscopic examination:** All samples were examined for fungal elements under a light microscope at  $\times 40$  magnification using 20% KOH / DMSO (Merck Co., Darmstadt, Germany).

**Culture and identification:** All samples were inoculated onto Mycosel agar (Merck Co., Darmstadt, Germany). The plates were incubated at 27°C and examined daily for four weeks. Dermatophyte isolates were identified by colony morphology and microscopic examination with lactophenol cotton blue preparation.

**Statistical analysis:** The chi-square ( $\chi^2$ ) test was used to assess statistical differences between the groups. Comparisons of prevalence between male versus female and long-haired cats versus short-haired cats were made using the  $\chi^2$  test for two inde-

pendent proportions. Comparisons of three or more prevalences (four age categories and four seasons) were made using the  $\chi^2$  test for multiple independent proportions. Agreement between the results of the two methods used to examine the animals was evaluated by Kappa statistics. All statistical analyses were performed with the SPSS software for Windows (version 26) and  $p < 0.05$  was considered statistically significant.

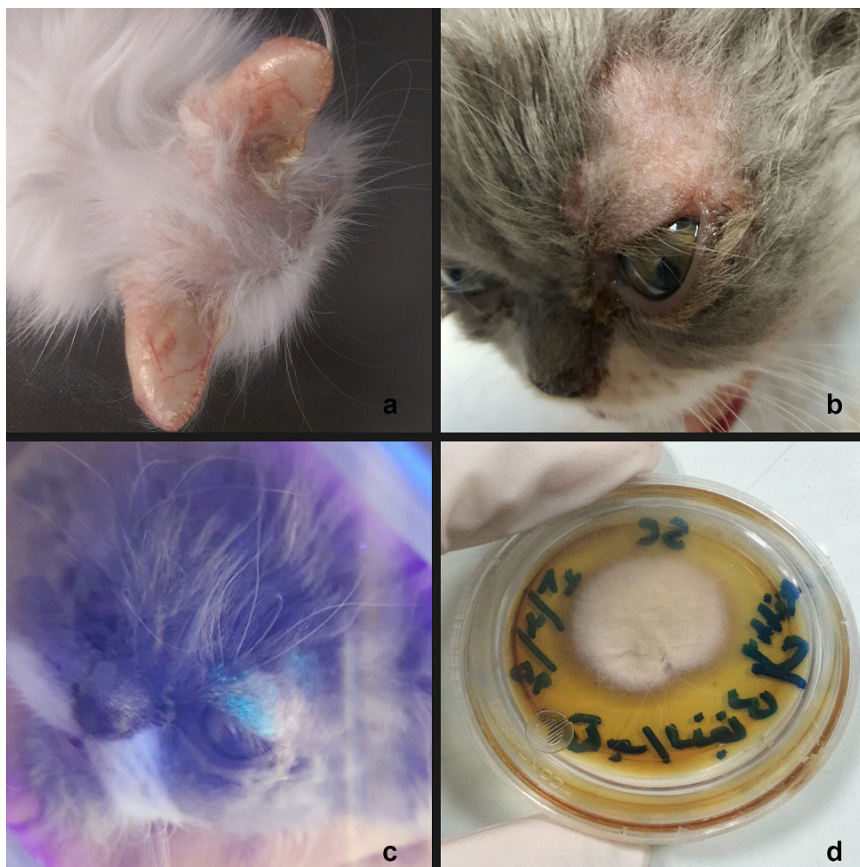
**Results:** Of the 122 examined samples, 90 (73.77%) were positive for fungal elements by direct microscopic examination and 66 (54%) were also culture-positive. Three (2.45%) samples considered negative upon direct microscopic examination yielded positive cultures for dermatophytes. Agreement between the tests was moderate as shown by the kappa value of  $k = 0.49$  between direct microscopy and fungal culture ( $p < 0.05$ ). According to the culture results, *M. canis* (54%) was the only dermatophyte species isolated from the cats (Fig. 1).

In the present study, the lesions of dermatophytosis mostly appeared as one or more irregular or annular areas of alopecia with or without scales, with the trunk (27/66), ears (24/66) (Fig. 1a), and face (18/66) (Fig. 1b and 1c) affected most commonly according to culture results (Table 1). Overall, most of the infected cats presented the generalized distribution pattern of the disease.

The infection had no statistically significant asso-

ciation with the gender or hair type of the cats. According to our model, the only risk factor found to be significantly associated with infection was age. Cats younger than 7 months of age showed a statistically higher prevalence of infection than older animals ( $p < 0.001$ ). The isolation rate of dermatophytes was relatively high in the winter. However, no statistically significant difference was detected in the seasonal distribution of feline dermatophytoses. The variables are reported in Table 2.

According to the results of the present study, among 122 examined samples, 90 (73.77%) were positive for fungal elements by direct microscopic examination and 66 (54%) were culture-positive. While 3 (2.45%) negative samples at direct microscopic examination had positive culture, 26 (21.31%) positive samples at direct microscopy had negative culture. Agreement between the examination methods was moderate as shown by the kappa value of  $k = 0.49$  between direct microscopy and fungal culture. Thus, it can be concluded that direct microscopic examination can be helpful in the diagnosis of dermatophytoses as previously mentioned by other researchers [5]. However, we suggest that veterinary practitioners wait for the culture results to initiate sufficient treatment. Sparkes et al. (1993) emphasized that direct microscopy had positive predictive values



**Figure 1.**

Scaling and alopecia of both ears of a 6-month-old Persian cat with generalized dermatophytosis (a). Focal lesion of dermatophytosis on an otherwise healthy cat. Note the scaling, erythematous and crusting lesions in addition to alopecia in this 50-days-old Persian cat (b). The extent of lesions is highlighted by Wood's lamp (c). The culture result of the same cat is positive for *M. canis* (d).

**Table 1.**

Anatomical distribution of skin lesions in positive cats according to direct microscopic evaluation and culture positive results

Anatomical location	DM	Culture
Head	8	6
Face	31	18
Ears	25	24
Cervial	20	19
Trunk	32	27
Forelimbs	9	8
Hindlimbs	5	3
Onycho	4	3
Tail	11	8

of 93% and negative predictive values of 93% in determining the presence of dermatophytosis.

They stated that cultural examination alone was not enough for dermatophytosis diagnosis because of the occurrence of false positive and false negative results [7].

According to the results of the present study, only 26 negative culture samples were reported out of 122 samples, which seems to be an acceptable success. This difference in direct microscopic examination and culture results may be attributed to the sampling conditions and sample volume as well as the sensitivity of the strain to the culture medium used (SCC). Because of the existing conditions, re-sampling and using other culture media (i.e., culture media enriched with vitamins and amino acids) was not possible in the current study. It should also be noted that if a sufficient sample size was available, in cases where the direct test was positive and the culture was negative (the direct test was typically positive), sometimes the culture was repeated up to 5 times but the dermatophyte did not grow.

Our findings showed that 66 (54%) of sampled cats referred to our veterinary teaching hospital were culture-positive of which 100% of isolated dermatophytes were *M. canis*. The results cannot be generalized to the general population and also should be carefully interpreted. Some of the previous studies indicated a high prevalence of feline dermatophytosis (e.g., more than 90% as reported by Lewis et al., 1991 and Polak et al., 2014) [6, 12] and similar to the present study, *M. canis* was the most commonly isolated species in the cats with a suspected lesion of dermatophytosis. However, in Iran, two other investigations reported much lower prevalences of 25.76% and 54.8% [4, 13].

**Table 2.**

Prevalence of *M. Canis* in cats in relation to different variables

Variables	No. animal tested/ No. positive animal (%)
<b>Gender</b>	
Female	<b>64 / 29 (45.3%)</b>
intact	50 / 21
neutred	3 / 0
undetermined	11 / 8
Male	<b>51 / 30 (58.5%)</b>
intact	31 / 17
neutred	4 / 0
undetermined	16 / 13
Undetermined	7 / (5.73%)
<b>Age</b>	
≤ 7 mos	38 / 27 (71%)
7 mos-2 yrs	46 / 13 (28.3%)
≥ 2 yrs-6 yrs	8 / 1 (12.5%)
≥ 6 yrs	3 / 1 (33.3%)
undetermined	27 / 23 (85.2%)
<b>Hair type</b>	
Long hair	95 / 50 (52.63%)
Short Hair	27 / 16 (59.2%)
<b>Season</b>	
Spring	27 / 12 (44.4%)
Summer	21 / 13 (61.9%)
Autumn	65 / 33 (50.8%)
Winter	9 / 8 (88.8%)

In addition, according to a recent study by Eidi et al. (2022), *M. canis* was the only species found in dogs and cats [24]. Similar to the present study, others have found that among 14 of the 38 (36.8%) culture-positive feline specimens from Brazil, 100% of isolates were *M. canis* [10]. Moreover, recently, researchers reported the isolation of *M. canis* from 60/76 lesional cats [12]. Interestingly, they emphasized that “half of the cultured dermatophytes were believed to be truly infected and half were believed to be fomite carriers”. Cats are the principal reservoir for *M. canis* and the

high rate of *M. canis* isolation in cats was not an unexpected result.

Authors reported different rates of *M. canis* isolation and other dermatophytes from asymptomatic cats with a much lower rate than the symptomatic cases [25]. As a result, it can be concluded that there is a high chance of isolating *M. canis* from symptomatic cats in contrast to asymptomatic cats.

Similar to Lewis et al. (1991), one of the findings of the present research is that most of the infected cats exhibited the generalized distribution pattern of dermatophytosis involving more than one region. Sites of predilection include the trunk, ears, neck, and face. It must, however, be borne in mind that in contrast to previous studies [8, 12], the present investigation revealed a more detailed picture of the suspected lesions of dermatophytosis leading to a more accurate diagnosis of clinical dermatophytosis.

According to the present study, cats younger than 7 months of age presented a significantly higher rate of infection than older animals. Others reported similar findings concerning the age of animals [5, 9-11]. The higher susceptibility of young cats with skin lesions suspicious of dermatophytoses might be due to their immunological immaturity, the deficiency of fungistatic sebum or linoleic acid, biochemical exchange on the skin, and the physiological status of the animals [5, 6, 9, 26, 27].

We observed no statistically significant difference between male and female cats and between intact or neutered cats. Similarly, some previous studies did not find any correlation between gender and the occurrence of dermatophytosis in cats [5, 28]. In contrast, some other authors reported a higher prevalence of dermatophytosis in male or female cats; for example, Boyanowski et al. (2000) reported that neutered male cats had a 12-fold higher risk of having dermatophytosis compared to intact male cats [29]. Furthermore, Natale et al. (2007) detected a significantly higher prevalence in female cats, which might be due to the disproportion between male and female cats examined [30].

The results of the present study revealed no significant differences in the prevalence of dermatophytosis between long-haired and short-haired cats. Others found a higher percentage of *M. canis* in healthy long-haired or Persian cats. However, they did not perform a statistical analysis to check the significance of their results [10, 31]. In addition, Mancianti et al. (2002) examined symptomatic animals and found a higher percentage in long-haired cats [9]. There is indirect evidence that long-haired cats (e.g., Persian cats) are predisposed to dermatophytosis. This breed is commonly over-represented in the general cat population and also in treatment studies, supporting the obser-

vation that Persian cats are predisposed to dermatophytosis [32]. Moriello et al. (1991) provided an explanation for the more common isolation of *M. canis* in long-haired breeds. In their study on cats with and without dermatophytosis, they did not find any significant difference in hair length for the isolation of *M. canis*. They thought it is possible that *M. canis* is more difficult to be removed from long-haired cats [32].

Data on the seasonality of dermatophytoses in the literature are controversial and according to several authors, there is no correlation between the season and the occurrence of dermatophytoses [7-9, 11]. In the current research, the isolation rate of dermatophytes was relatively high in the winter. However, no statistically significant difference was identified in the seasonal distribution of feline dermatophytoses. The climate of our study region (Mashhad) is semi-arid with low humidity, cold winters, and moderate summers. Some authors suggest that the highest prevalence of dermatophytosis is found in the cold seasons. A 15-year study in Italy on 7650 suspect pet cats showed a significantly higher recovery rate for *M. canis* in the fall and winter than in summer and spring [9]. They reported a higher prevalence, but the significance is unclear.

In conclusion, further research with a larger survey is needed to get a better estimation of the prevalence and to identify the possible risk factors of dermatophytosis in cats. The information acquired in this study has provided helpful insights into dermatophytoses in northern Iran highlighting the most important clinical and mycological features of skin mycoses in pet cats.

## Acknowledgements

We thank Mr. Ali Jeddi for his technical assistance during the study.

## Conflicts of Interest

Authors declare that they have no conflicts of interest.

## Authors' Contributions

JK conceived and planned the study. ZGT and JK carried out the samplings and contributed to sample preparation. The procedures of mycology have been conducted by SE. JK contributed to the interpretation of the results and took the lead in writing the manuscript.

## References

- Frymus T, Gruffydd-Jones T, Pennisi MG, Addie D, Belák S, Boucraut-Baralon C, Egberink H, Hartmann K, Hosie MJ, Lloret A, Lutz H, Marsilio F, Möstl K, Radford AD, Thiry E, Truyen U, Horzinek MC. (2013): Dermatophytosis in cats: ABCD guidelines on prevention and management. *Journal of Feline Medicine and Surgery*. 2013; 15: 598-604.
- Khoshnegah J, Movassaghi AR, Rad M. Survey of dermatological conditions in a population of domestic dogs in Mashhad, northeast of Iran (2007-2011). *Veterinary Research Forum*. 2013; 4 (2):99-103.
- Shams-Ghahfarokhi M, Mosleh-Tehrani F, Ranjbar-Bahadori S. An epidemiological survey on cattle ringworm in major dairy farms of Mashhad city, Eastern Iran. *Iranian Journal of Microbiology*. 2009; 1(3):31-36.
- Shokri H, Khosravi A. An epidemiological study of animals dermatomycoses in Iran. *Journal of Medical Mycology*. 2016; 26: 170-77.
- Seeker E and Dogan N. Isolation of dermatophytes from dogs and cats with suspected dermatophytosis in Western Turkey. *Preventive Veterinary Medicine*. 2011; 98 (1): 46-51.
- Lewis DT, Foil CS, Hosgood G. Epidemiology and clinical features of dermatophytosis in dogs and cats at Louisiana State University: 1981-1990. *Veterinary Dermatology*. 1991; 2: 53-58.
- Sparkes AH, Gruffydd-Jones TJ, Shaw SE, Wright AI, Stokes CR. Epidemiological and diagnostic features of canine and feline dermatophytosis in the United Kingdom. *Veterinary Record*. 1993; 133: 57.
- Cabañes FJ, Abarca ML, Bragulat MR. Dermatophytes isolated from domestic animals in Barcelona, Spain. *Mycopathologia*. 1997; 137: 107-113.
- Mancianti, F, Nardoni S, Cecchi S, Corazza M, Taccini F. Dermatophytes isolated from symptomatic dogs and cats in Tuscany, Italy during a 15-year-period. *Mycopathologia*. 2002; 156:13-18.
- Brilhante RS, Cavalcante CS, Soares-Junior FA, Cordeiro RA, Sidrim JJ, Rocha MF. High rate of *Microsporum canis* feline and canine dermatophytoses in Northeast Brazil: epidemiological and diagnostic features. *Mycopathologia*. 2003; 56: 303-308.
- Cafarchia C, Romito D, Sasanelli M, Lia R, Capelli G, Otranto D. The epidemiology of canine and feline dermatophytoses in southern Italy. *Mycoses*. 2004; 47: 508-513.
- Polak K, Levy J, Crawford P, Leutenegger C, Moriello K. Infectious diseases in large-scale cat hoarding investigations. *Veterinary Journal*. 2014; 201: 189-95.
- Khosravi A, Mahmoudi M. Dermatophytes isolated from domestic animals in Iran. *Mycoses*. 2003; 46: 222-225.
- Deboer DJ, Moriello KA. Clinical update on feline dermatophytosis - part I. *Compendium on Continuing Education*. 1995; 17: 1197.
- Miller WH, Griffin CE, Campbell KL. Fungal and algal skin disease. In: Muller and Kirk's Small Animal Dermatology. 7th edition. St Louis, MO: Elsevier, 2013; 231-83.
- Scott DW, Miller WH. Disorders of the claws and claw bed in cats. *Compendium on Continuing Education*. 1992; 14: 449.
- Carney HC, Moriello KA. Dermatophytosis: Cattery management plan. In Griffin CE, et al, editors: *Current Veterinary Dermatology*, St. Louis, Mosby-Year Book, 1993; 34.
- FOIL CS. Dermatophytosis. In Griffin CE, et al, editors: *Current Veterinary Dermatology*, St. Louis, Mosby-Year Book, 1993; 22.
- Larsson CE, Nahas CR, Ledon ALBP, Gambale W, Paula CR, Correa B. Ringworm in domestic cats in Sao Paulo, Brazil, between 1981-1990. *Feline Practice*. 1994; 22: 11-14.
- Statistical Center of Iran. Country's population estimation by urban and rural areas, 2010-2016. <http://amar.org.ir> (viewed 09.08.2017).
- Moriello KA. Diagnostic techniques for dermatophytosis. *Clin Tech Small Animal Practice* 2001; 16: 219-224.
- Robert R, Pihet M. Conventional methods for the diagnosis of dermatophytosis. *Mycopathologia*. 2008; 166: 295-306.
- Hoyumpa Vogt A, Rodan I, Brown M, Brown S, Buffington CA, Larue Forman MJ, Neilson J, Sparkes A. AAEP-AAHA: feline life stage guidelines. *Journal of Feline Medicine and Surgery*. 2010; 12: 43-54.
- Lavari A, Eidi S, Soltani M. Molecular diagnosis of dermatophyte isolates from canine and feline dermatophytosis in Northeast Iran. *Veterinary Medical Science* 2022; 8(2): 492-497.
- Mignon B, Losson B. Prevalence and characterization of *Microsporum canis* carriage in cats. *Journal of Medical and Veterinary Mycology*. 1997; 135: 249-56.
- Marchisio VF, Gallo MG, Tullio V, Nepote S, Piscozzi A, Cassinelli C. Dermatophytes from cases of skin disease in cats and dogs in Turin, Italy. *Mycoses*. 1995; 38: 239-244.
- Pinter L, Jurak Ž, Ukalović M, Sušić V. Epidemiological and clinical features of dermatophytoses in dogs and cats in Croatia between 1990 and 1998. *Veterinarski Arhiv*. 1999; 69: 261-270.
- Huisman EAP. Risk factors of feline dermatophytosis in the Netherlands. Faculty of Veterinary Medicine Theses. Master thesis. 2013

29. Boyanowski KJ, Ihrke PJ, Moriello KA, Kass PH. Isolation of fungal flora from the hair coats of shelter cats in the Pacific coastal USA. *Veterinary Dermatology*. 2000; 11: 143-150.
30. Natale A, Frangipane di Regalbono A, Zanellato G, Cavalletto M, Danesi P, Capelli G, Pietrobelli M. Parasitological survey on stray cat colonies from the Veneto Region. *Veterinary Research Communication*. 2007; 31: 241-244.
31. Antos I, Breuerstrosberg R, Awadmasalmeh M. Dermatophytes in clinically healthy cats and dogs in Vienna/Austria. *Wien Tierarztl Monatsschr*. 1996; 90: 124-130.
32. Moriello KA, Coyner K, Paterson S, Mignon B. Diagnosis and treatment of dermatophytosis in dogs and cats: Clinical consensus guidelines of the World Association for Veterinary Dermatology. *Veterinary Dermatology*. 2017; 28: 266-268.

**COPYRIGHTS**

©2022 The author(s). This is an open access article distributed under the terms of the Creative Commons Attribution (CC BY 4.0), which permits unrestricted use, distribution, and reproduction in any medium, as long as the original authors and source are cited. No permission is required from the authors or the publishers.

**How to cite this article**

Ghiasi Tarzi Z, Eidi S, Khoshnegah J. Clinical and Mycological Features of Dermatophytosis in Domestic cats at Ferdowsi University of Mashhad Veterinary Teaching Hospital. *Iran J Vet Sci Technol*. 2022; 14(4):52-58.

DOI: <https://doi.org/10.22067/ijvst.2022.75463.1123>

URL: [https://ijvst.um.ac.ir/article\\_43282.html](https://ijvst.um.ac.ir/article_43282.html)