



## Concurrent Coccidiosis and Bovine Papular Stomatitis Infection in Calves

H.A. Seifi<sup>1</sup>, A.R. Movassaghi<sup>2</sup>, M. Mohri<sup>1</sup>, M. Rad<sup>2</sup>,  
M.R. Aslani<sup>1</sup>, A. Parand<sup>3</sup>, Gh. Razmi<sup>2</sup>

Departments of <sup>1</sup>Clinical Sciences and <sup>2</sup>Pathobiology  
School of Veterinary Medicine, Ferdowsi University of Mashhad  
Mashhad 91775-1793, Iran

(Received September 21, 1999; accepted June 16, 2000)

### Abstract

Seifi, H.A., Movassaghi, A.R., Mohri, M., Rad, M., Aslani, M.R., Parand, A. and Razmi, Gh. 2000. Concurrent coccidiosis and bovine papular stomatitis infection in calves. J. Appl. Anim. Res., 18: 103-108.

*A group of 23 calves (2-3 months) showed diarrhoea after weaning and short distance transportation. Buccal cavity lesions of papular nature on the muzzle, gingivae, buccal papillae, inner surface of the lips and hard palate were observed. Buccal cavity lesions showed hyperplastic epithelium which consisted of focal areas of ballooning degeneration. Eosinophilic intracytoplasmic inclusion bodies, characteristic of bovine papular stomatitis were seen in the affected cells. At necropsy, sexual and asexual forms of coccidia were determined on the epithelium of the caecal and colonic crypts. Large number of oocysts were detected on the faecal examination. All the affected calves were treated by intramuscular injection of sulphadimidine. Newly weaned calves were fed lasolosid as prophylaxis. One month after the onset of outbreak, the syndromie subsided.*

Key words: Calf, coccidiosis, bovine papular stomatitis, diarrhoea, oral lesions.

---

<sup>3</sup>Private practitioner.

### Introduction

This report describes an outbreak of concurrent infections of coccidiosis and bovine papular stomatitis in a group of calves. It highlights the importance of thorough clinical examination and appropriate laboratory tests for differential and confirmed diagnosis in cases with oral lesions and diarrhoea.

### Case Report

In a self-contained dairy herd of 500 cows, where 45 weaned calves had been transported to other part of the farm at 5 km distance, a group of 23 calves showed non-fetid, greenish diarrhoea with small streaks of blood; mild to moderate dehydration and normal to mild (40°C) elevated rectal temperature with fair appetite 5-15 days after weaning and transportation. Systemic treatment with enrofloxacin (2.5 mg/kg daily for 3 days) was ineffective. Close physical examination revealed buccal cavity lesions on hard palate, beneath the tongue and muzzle. In 6 cases oral lesions without diarrhoea were observed. The oral and muzzle lesions were biopsied for histopathological examination.

One affected calf was euthanized due to poor condition one week post outbreak and necropsy was conducted.

Eleven days after the onset of the outbreak, 3 cases developed severe dysentery and dehydration. Perineums and tails of the calves were smudged with blood-stained diarrhoea, and straining was evident. But anaemia was not a feature.

Blood samples were collected from all affected calves for haematology. Faeces were examined for cryptosporidia using modified Ziehl-Neelson (Garcia *et al.*, 1983) stained smears and for coccidia using centrifugal flotation (with salt) technique (Soulsby, 1982).

The collected faecal samples were cultured for salmonella by overnight enrichment of 2 g faecal samples in 20 ml of selenite broth, with subculture to Xylose-Lysine-Desoxycholate (XLD) agar and McConkey agar plates. After incubation for 24 hours at 37°C, suspected colonies were examined by routine biochemical tests (Sleigh and Duguid, 1989).

### Pathological findings

**Oral lesions:** At first, the lesions were small, red, hyperaemic foci, 5 to 10 mm in diameter on the muzzle, gingivae, buccal papillae and hard palate. After 5-7 days, the lesions enlarged and papules were formed. In some cases, the lesions were surrounded with a reddish periphery. Finally, the lesions became ulcerated and eroded, leaving a cratered appearance. The ulcers were confluent and large ulcers were formed. The muzzle was much more prominent in the oral cavity behind the incisors.

Microscopically, the epithelium showed focal areas of ballooning degeneration, nuclear pyknosis with a clear cytoplasm and eosinophilic intracytoplasmic inclusions characteristic of bovine papular stomatitis virus.

**Postmortem findings:** The animal was emaciated. The hindquarters were stained with blood. The mucosal surface of the intestine

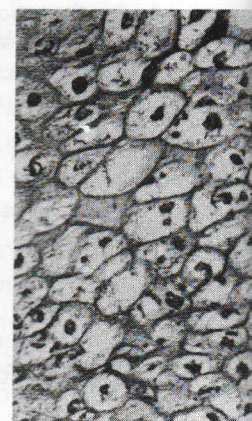


Fig. 1: Marked hydropic degeneration of epithelial cells accompanied by intracytoplasmic eosinophilic inclusions (H & E stain x 512).

*Pathological findings*

*Oral lesions:* At first, the lesions were recognized grossly as small hyperaemic foci, 5 to 10 diameter. These macules were seen on the muzzle, gingivae, buccal papillae, inner surface of the lips and hard palate. After 5-7 days, the center of these macules became elevated and papules were formed. In this stage, lesions appeared like a coin with a reddish periphery. Finally, the central zones were sloughed and eroded, leaving a craterous like lesions. Many of these lesions were confluent and large ulcers were formed. This type of lesion was much more prominent on the dental pad and the floor of the oral cavity behind the incisors.

Microscopically, the epithelium was hyperplastic and consisted focal areas of ballooning degeneration. In affected cells, nuclei were pyknotic with a clear cytoplasm. Many of these cells, contained eosinophilic intracytoplasmic inclusion bodies (Fig. 1), which were characteristic of bovine papular stomatitis.

*Postmortem findings:* The animal was cachectic and dehydrated and the hindquartes were stained with blood-stained diarrhoea. The mucosal surface of the intestines was oedematous and hyperaemic.

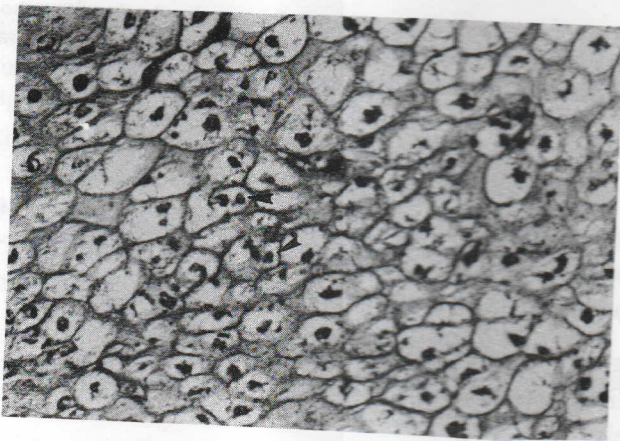


Fig. 1: Marked hydropic degeneration of epithelial cells of the stratum spinosum, accompanied by intracytoplasmic inclusion bodies (arrows). Haematoxylin - eosin (H & E) stain x 512.

There were erosions with a fibrinonecrotic exudate and bleeding was an important finding.

Large intestines contained **bloody fluid**. These findings indicated a fibrino-haemorrhagic **typhlocolitis**. Microscopically, the epithelium of the caecal and **colonic crypts** was destroyed accompanied by a severe **inflammatory reaction** in the lamina propria. Sexual and asexual forms of **coccidia** were determined in affected zones (Fig. 2).

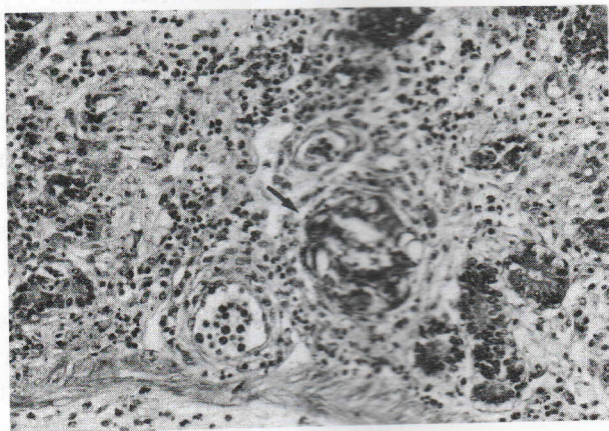


Fig. 2: Villous atrophy and destruction of intestinal glands associated with infiltration of inflammatory cells. Epithelial cells contain stages of the *Eimeria* life cycle (arrow). Haematoxylin - eosin (H & E) stain x 256.

#### *Clinicopathological findings*

**Haematology:** Haematological changes were not marked. Only, there were leukocytosis and neutrophilia in three cases and PCV were elevated above normal range in two cases.

**Microbiology:** cultures of several samples of faeces of affected calves and intestinal contents and liver of the necropsied calf for recovery of salmonella was negative.

Faeces examination for cryptosporidia and coccidia was negative on day 6 of the outbreak. But on day 11, large number of oocysts (*Eimeria bovis* and *E. zurenu*) were observed.

#### *Diagnosis and treatment*

On the basis of the clinical findings a diagnosis of concurrent papular stomatitis virus was

The calves were treated with flumequine (150 mg/kg daily) and were infused by intravenous fluids. They were fed lasalosis (50 mg/kg) as a treatment protocol instituted in diarrhoeic calves favourably. The buccal lesions were treated and there were few lesions that

D

The concurrent infection of coccidia has not been recorded in the bovine papular stomatitis virus. Intercurrent diseases caused by coccidia (Radostits *et al.*, 1994). A concurrent infection of papular stomatitis and bovine virus diarrhoea virus (Bohac and Yates, 1980).

On the other hand, field studies in cattle is immunosuppression. Susceptibility to other common diseases in this outbreak, it was not possible to determine. The primary cause of the outbreak may have lowered the resistance of calves to infection. In situations where distinct pathogens caused similar clinical signs, diagnosis may be confusing. A complete clinical examination followed to arrive at the correct

R

Bohac, J.G. and Yates, D.G. 1980. Concurrent papular stomatitis and

### *Diagnosis and treatment*

On the basis of the clinical, clinicopathological and hispathological findings a diagnosis of concurrent infection with coccidia and bovine papular stomatitis virus was made.

The calves were treated by intramuscular injections of sulphadimidine (150 mg/kg daily for 3 days) and severe dehydrated calves were infused by intravenous fluids. Healthy and newly weaned calves were fed lasalosisid (50 mg/kg) in ration as prophylaxis. After treatment protocol instituted, no calf died and one week later, diarrhoeic calves favourably responded to sulphadimidine administration. The buccal lesions began to regress and after one month, there were few lesions that did not affect the health of the calves.

### *Discussion*

The concurrent infection of coccidiosis and bovine papular stomatitis has not been recorded in the literature. It has been stated that the bovine papular stomatitis virus may only cause lesions when intercurrent diseases cause lowering of the animals resistance (Radostits *et al.*, 1994). A concurrent infection of bovine papular stomatitis and bovine virus diarrhoea has been described in a calf (Bohac and Yates, 1980).

On the other hand, field observations suggest that coccidiosis in cattle is immunosuppressive which may increase their susceptibility to other common infections (Roth *et al.*, 1989). However, in this outbreak, it was not possible to determine, which of the two diseases is the primary cause, but weaning and transportation stress may have lowered the resistance and increased susceptibility of the calves to infection. In situations, where concurrent infection of two distinct pathogens caused stomatitis and diarrhoea, differential diagnosis may be confusing. It is recommended that in such cases complete clinical examination supported by laboratory tests be followed to arrive at the correct diagnosis.

### *References*

- Bohac, J.G. and Yates, D.G. 1980. Concurrent bovine virus diarrhoea and bovine papular stomatitis infection in a calf. *Can. Vet. J.*, 21: 310-313.

- Garcia, L.S., Bruckner, D.A., Brewer, T.C. and Shimizu, R.Y. 1983. Techniques for recovery and identification of oocysts from stool specimens. *J. Clin. Micro.*, 18: 185-190.
- Radostits, O.M., Blood, D.C. and Gay, C.C. 1994. *Veterinary Medicine*, 8th edn. Bailliere Tindall. p. 1009.
- Roth, J.A., Jarvinen, J.A., Frank, D.E. and Fox, J.E. 1989. Alteration of neutrophil function associated with coccidiosis in cattle: influence of decoquinate and dexamethasone. *Am. J. Vet. Res.*, 50: 1250-1253.
- Sleigh, J.D. and Duguid, J.P. 1989. *Mackie and McCartney Practical Medical Microbiology*. 13th edn. Eds. J.G. Collee, J.P. Duguid, A.G. Fraser and B.P. Marmion, Churchill Livingstone. p. 456.
- Soulsby, E.J.L. 1982. *Helminth, Arthropods and Protozoa of Domesticated Animals*. 7th edn. Bailliere Tindall. p. 765.

एच.ए. सेफी, ए.आर. मोवास्साधी, एम. मोहरी, एम. रैड, एम.आर. अस्लानी, ए. परन्द, जी.एच. राज्मी। गोवत्सों में संगामी काक्सीडियोसिस और पैपुलरी मुख प्रदाह संक्रमण।

दुग्ध कट्टू 2-3 माह के 23 गोवत्सों को थोड़ी दूरी तक परिवहन के पश्चात् उनमें अतिसार प्रगट हुआ। थूथन, जीहा, मुँह की भीतरी भित्ति के अंकुरकों, होंठों की भीतरी सतह और कठोर तालु पर पैपुल पाए गये। मुख गुहा की विक्षतियों में फूले हुए अपक्षरण वाले केन्द्रीय क्षेत्रों में अतिवर्धित श्लेष्मल कला पाई गयी। प्रभावित कोशाओं में इयोसिनोफिली कोशिका द्रव के समावेशन काय गोवंशी पैपुलरी मुख प्रदाह के विशिष्ट लक्षण थे। शवच्छेद परीक्षण पर बृहद्आन्त्र और सर्पिल आंत्र की श्लेष्मल कला में लैंगिक और अलैंगिक काक्सीडिया पाए गये। उनके मल परीक्षण में अधिक संख्या में काक्सीडिया के अंडे पाए गये। सभी प्रभावित गोवत्सों का सल्फाडिमीडीन के अंतरामांसली टीकाकरण से उपचार किया गया। रोग निरोध हेतु तुरंत दुग्ध कट्टू गोवत्सों को लैसोलोसिड दिया गया। संक्रमण लगभग एक माह में ही लुप्त हो गया।