

First report of *Neospora caninum*-associated bovine abortion in Mashhad area, Iran

G. R. Razmi · M. Maleki · N. Farzaneh ·
M. Talebkhan Garoussi · A. H. Fallah

Received: 22 June 2006 / Accepted: 28 August 2006 / Published online: 6 October 2006
© Springer-Verlag 2006

Abstract *Neospora caninum* is an apicomplexan protozoan which causes abortion in cattle worldwide. The present study was designed to assess the importance of bovine neosporosis for causing abortion in Iranian cattle. Infection was primarily diagnosed by polymerase chain reaction (PCR), complemented with histopathology and immunohistochemistry (IHC). One hundred brains of aborted bovine fetuses were collected from Iranian dairy herd between 2003 and 2005 in Mashhad area. *N. caninum* was detected by PCR in the brains of 13 aborted fetuses. Lesions consistent with *N. caninum* infection were observed in 12 of fetal brains. Immunohistochemical examination of brain detected *N. caninum* organisms in three aborted fetuses, and a thick-walled (2 µm) cyst with 50 µm diameter was identified in one of the IHC-positive brain. The results indicated that neosporosis is an important cause of abortion in dairy cattle of Iran.

Introduction

Neospora caninum is a recently recognized protozoan parasite of livestock and companion animal (Dubey et al. 1988). Neosporosis has been described an important cause of abortion in cattle worldwide (Dubey and Lindsay 1996). Cattle may be infected transplacentally or as result of

ingesting oocyst produced by dogs, which represent the definitive host. Cattle at any age may abort from 3 months of gestation to term, and abortion is the main clinical sign observed. Fetuses may die in utero, be resorbed, mummified, autolyzed, stillborn, born alive but diseased or born clinically normal but chronically infected (Dubey and Lindsay 1996; Dubey 2005). In Iran, antibodies to *N. caninum* were reported in sera of dairy cattle (Razmi et al. 2002, 2006; Sadrebazzaz et al. 2004). Recently, in a preliminary study in Iran, *N. caninum* DNA had been detected by polymerase chain reaction (PCR) in brains from four out of six aborted fetuses (Habibi et al. 2005). But there is not any data about abortion due to *N. caninum* in dairy cattle in Iran. We reported, here, the first cases of confirmed neosporosis in aborted bovine fetuses from Iran.

Materials and methods

Field study area

The study was done in Mashhad area, capital city of the Khorasan province, situated in the northeast of Iran. The Khorasan province is located in northern temperature zone. The climate is semi-arid with cold winters and moderate summer. The province has an estimated 25,000 cattle on 110 dairy farms. The herd size varied from farm to farm with a range of 30 to 2,000 cattle. The most common breed of cattle were Holstein/Friesian.

Sample collection

One hundred aborted bovine fetuses at different stages of gestation were collected and examined during 2003 to 2005. At necropsy, the skull was opened under aseptic

G. R. Razmi (✉) · M. Maleki
Department of Pathobiology, School Veterinary Medicine,
Ferdowsi University of Mashhad,
P.O. Box 91775-1793, Mashhad, Iran
e-mail: razmi@ferdowsi.um.ac.ir

N. Farzaneh · M. Talebkhan Garoussi · A. H. Fallah
Department of Clinical Science,
School of Veterinary medicine of Mashhad,
Mashhad, Iran

condition and one-half of the brain was sampled for PCR, and the other half, for histopathology examination.

DNA isolation and PCR

One-half of the brain was homogenized with a stirrer, and DNA was extracted from 1 g homogenate sample using the DNA™ Kit (Cinnagen, Iran) according to the manufacturer's recommendations. PCR was done as previously described (Müller et al. 1996) with *N. caninum*-specific primers NP21plus (5'CCCAGTGCGTCCAATCCTGTAAC3') and Np6plus (5'CTCGCCAGTCAACCTACGTCTTCT3').

Histopathology and immunohistochemistry

Brain tissue samples were fixed in 10% neutral buffered formalin and embedded in paraffin. Sections (5 µm) were cut and stained with haematoxyline and eosin (HE) (Kiernan 1990). The stained sections were histopathologically assessed by light microscopy. An indirect peroxidase technique was used for immunohistochemical staining (Kendrich et al. 2001; Gottstein et al. 1998). To determine lesion and evaluate the parasite distribution in each brain, three sections were carefully examined at ×400 and ×1,000 magnification.

Results

N. caninum DNA was detected in 13 (13%) out of 100 fetal brain samples. Among the 100 brain fetuses, only 53 cases were suitable for histopathological examination. Of these 53 cases, 12 (22.6%) cases had the characteristic lesion of *Neospora* infection such as non-supportive necrotic foci (Fig. 1).

Immunohistochemically, parasites were detected in three (5.6%) of the 53 brain samples. A thick-walled (2 µm) cyst with 50 µm diameter without septa and secondary cyst wall was identified in one IHC-positive brain (Fig. 2). This sample was again searched by PCR and detected *N. caninum* DNA. A comparison between PCR and histopathological results showed that *N. caninum* DNA was detected in seven (58%) out of 12 brains with detectable cerebral lesions (Table 1).

Discussion

In this study, we used PCR with histopathological examination for the diagnosis of *N. caninum* infection in 100 aborted fetuses and to evaluate the association of *N. caninum* infection with abortion in dairy cattle of Iran. PCR was considered to be a highly specific and sensitive technique for detection of *N. caninum* in brain of aborted fetuses and was less affected by autolysis and histopathol-

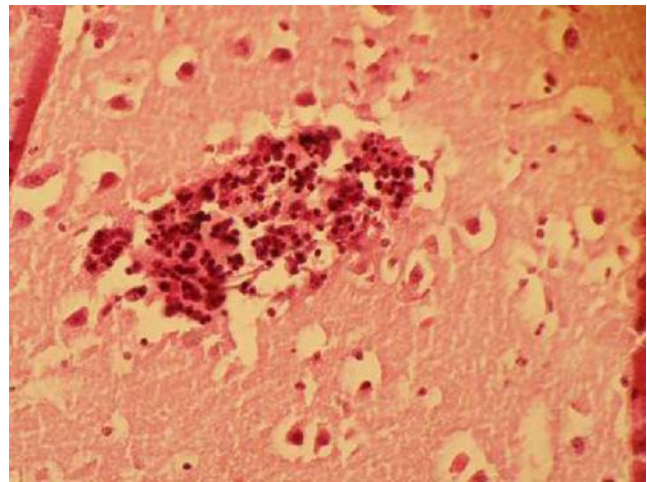


Fig. 1 Fetal brain with a central necrotic focus surrounded by mononuclear cell infiltration (HE×400)

ogy (Sager et al. 2001). This method has become important in the diagnosis of *N. caninum* abortion in cattle, when PCR results can be associated to histopathology finding in aborted fetal tissues. By using PCR, *N. caninum* DNA was detected in 13% (13) of brain samples. In association to a previous report in Iran (Habibi et al. 2005), it seems that the prevalence of *N. caninum* DNA infection is high in the brains of bovine aborted fetuses. Histopathologically, the characteristic lesions of *Neospora* infection, such as non-suppurative necrotic (Barr et al. 1990; Dubey and Lindsay 1993; Dubey et al. 1998; Morales et al. 2001; Wouda et al. 1997) were observed in 12 (22%) out of 53 brain samples. *N. caninum* DNA was detected in seven (58%) of 12 cases with cerebral necrotic lesions by PCR that provided a solid evidence for *N. caninum* to be the cause of abortion. But in five (41%) out of 12 cases, we found cerebral necrotic lesions without detectable *N. caninum* DNA. Due to the

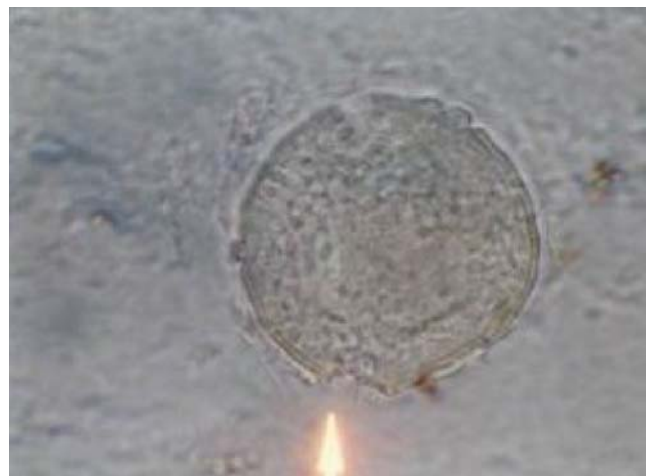

Fig. 2 IHC identification of tissue cyst of *Neospora caninum* with numerous bradyzoite enclosed in a thick cyst wall (arrow) in the brain of an aborted bovine fetus, ×1,000

Table 1 Comparison between results of *N. caninum* PCR, histopathological and immunohistochemical (IHC) finding of fetal brains examined

Histopathological, immunohistochemical finding	PCR		Total
	+	–	
Necrosis (+), IHC (+)	1	2	3
Necrosis (+), IHC (–)	6	3	9
Necrosis (–), IHC (+)	0	0	0
Necrosis (–), IHC (–)	0	41	41
Not done	6	41	47
Total	13	87	100

fact that one-half of the brain was sampled for PCR and the other half for histological examination, additional cases may be missed, as parasites and parasitic lesions were distributed focally (Sager et al. 2001). On the other hand, when the degree of inflammatory changes is mild, PCR assay might not be able to detect *N. caninum*.

Baszler et al. (1999) suggested that a least 20 to 40 tachyzoites in 20 mg of tissue are needed to pursue PCR detection of *N. caninum* in clinical samples. In this study, *N. caninum* organisms were not found in any of these HE-stained sections, but immunohistochemically, tachyzoites and tissue cyst of *N. caninum* organisms were identified in three brain samples. Cyst tissue was round in shape, up to 50 µm long and had a predominantly thick cyst wall (2 µm). The observed cyst is in accordance with the morphology of *Neospora* cyst that is described in cattle (Dubey et al. 1989; Dubey and Schares 2006; Peter et al. 2001; Morales et al. 2001). Otherwise, the PCR method also confirmed *N. caninum* DNA infection in this sample. In the present study, we detected the *N. caninum* DNA in brains of bovine fetuses and reported the tissue cyst of *N. caninum* by IHC. The good correlation between PCR and histopathological finding results supported the hypothesis that *Neospora* infection is associated with bovine abortion in Iran. Further investigation is needed for epidemiological status of bovine neosporosis in dairy cattle of Iran.

Acknowledgements The authors give special thanks to Dr. Gottstein and Dr. Müller at the institute of Parasitology, Bern, Switzerland for providing the positive control PCR and the polyclonal *N. caninum* antiserum. We are very grateful to Mr. G.A. Azari and Mr. Mohammadnejad for their technical assistance. The authors would like to acknowledge the Khorasan Veterinary Office for providing information about farms and logistic support. The study was financially supported by Ferdowsi University of Mashhad, Iran.

References

Barr BC, Anderson ML, Blanchard PC (1990) Bovine fetal encephalitis and myocarditis associated with protozoan infection. *Vet Pathol* 27:354–361

- Baszler TV, Gay LJ, Long MT, Mathison BA (1999) Detection by PCR of *Neospora caninum* in fetal tissues from spontaneous bovine abortion. *J Clin Microbiol* 37:4059–4064
- Dubey JP (2005) Neosporosis in cattle. *Vet Clin North Am Food Anim Pract* 21:473–483
- Dubey JP, Lindsay DS (1993) Neosporosis. *Parasitol Today* 9:452–457
- Dubey JP, Lindsay DS (1996) A review of *Neospora caninum* and neosporosis. *Vet Parasitol* 67:1–59
- Dubey JP, Schares G (2006) Diagnosis of bovine neosporosis. *Vet Parasitol* 140:1–34
- Dubey JP, Carpenter JL, Speer CA, Topper MJ, Uggla A (1988) Newly recognized fatal protozoan disease of dogs. *J Am Vet Med Assoc* 192:1269–1285
- Dubey JP, Leather CW, Lindsay DS (1989) *Neospora caninum*-like protozoan associated with fatal myelitis in newborn calves. *J Parasitol* 75:146–148
- Dubey JP, Abbit B, Topper MJ, Edwards JF (1998) Hydrocephalus associated with *Neospora caninum* infection in an aborted bovine fetus. *J Comp Pathol* 118:169–173
- Gottstein B, Hentrich B, Wyss R, Thür B, Busato A, Stärk KDC, Müller N (1998) Molecular and immunodiagnostic investigation and bovine neosporosis in Switzerland. *Intern J Parasitol* 28:679–691
- Habibi GR, Hashemi-Fesharaki R, Sadrebazzaz A, Bozorgi S, Bordrar N (2005) Seminested PCR for diagnosis of *Neospora caninum* infection in cattle. *Arch Razi Ins* 59:55–64
- Kendrick JM, Neil MH, Nicholas RG (2001) Immunohistochemical methods. In: Howard GC, Bethell DR (eds) *Basic method in antibody production and characterization*. CRC, England, pp 239–264
- Kiernan JA (1990) *Histological and histochemical methods: theory and practice*. Pergamon, England, pp 96–97
- Morales E, Trigo FJ, Ibarra E, Puente E, Santacruz M (2001) Neosporosis in Mexican dairy herds: lesions and immunohistochemical detection of *Neospora caninum* in fetuses. *J Comp Pathol* 125:58–63
- Müller N, Zimmermann V, Heinrich B, Gottstein B (1996) Diagnosis of *Neospora caninum* and *Toxoplasma gondii* infection by PCR and DNA hybridization immunoassay. *J Clin Microbiol* 34:2850–2852
- Peter M, Lutkfels E, Heckerth AR, Schares G (2001) Immunohistochemical and ultrastructural evidence for *N. caninum* tissue cysts in skeletal muscles of naturally infected dogs and cattle. *Int J Parasitol* 31:1144–1148
- Razmi GR, Gottstein B, Naghibi A (2002) Primary estimation of *Neospora* infection in dairy cattle in Mashhad suburb, Iran. 3rd convention of Iranian Veterinary Clinicians. p 71 (Abstract English)
- Razmi GR, Mohammadi GR, Garossi T, Farzaneh N, Fallah AH, Maleki M (2006) Seroepidemiology of *Neospora caninum* infection in dairy cattle herds in Mashhad area, Iran. *Vet Parasitol* 135:187–189
- Sadrebazzaz A, Haddadzadeh H, Esmailnia K, Habibi GR, Vojgani G, Hashemi-Fesharaki R (2004) Serological prevalence of *N. caninum* in healthy and aborted dairy cattle in Mashhad, Iran. *Vet Parasitol* 124:201–204
- Sager H, Fischer I, Furrer K, Strasser M, Waldvogel A, Boerlin P, Audige L, Gottstein B (2001) A Swiss case-control study to assess *Neospora caninum*-associated bovine abortions by PCR, histopathology and serology. *Vet Parasitol* 102:1–15
- Wouda W, Moen AR, Visser IJR, Knapen F (1997) Bovine fetal neosporosis: a comparison of epizootic and sporadic abortion cases and different age classes with regard to lesion severity and immunohistochemical identification of organisms in brain, heart and liver. *J Vet Diagn Invest* 9:180–185